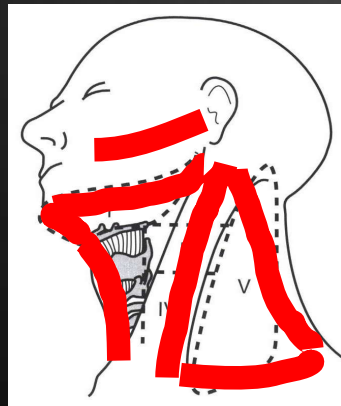


Ultrasound of the neck in 7 sweeps



rhian.rhys@wales.nhs.uk

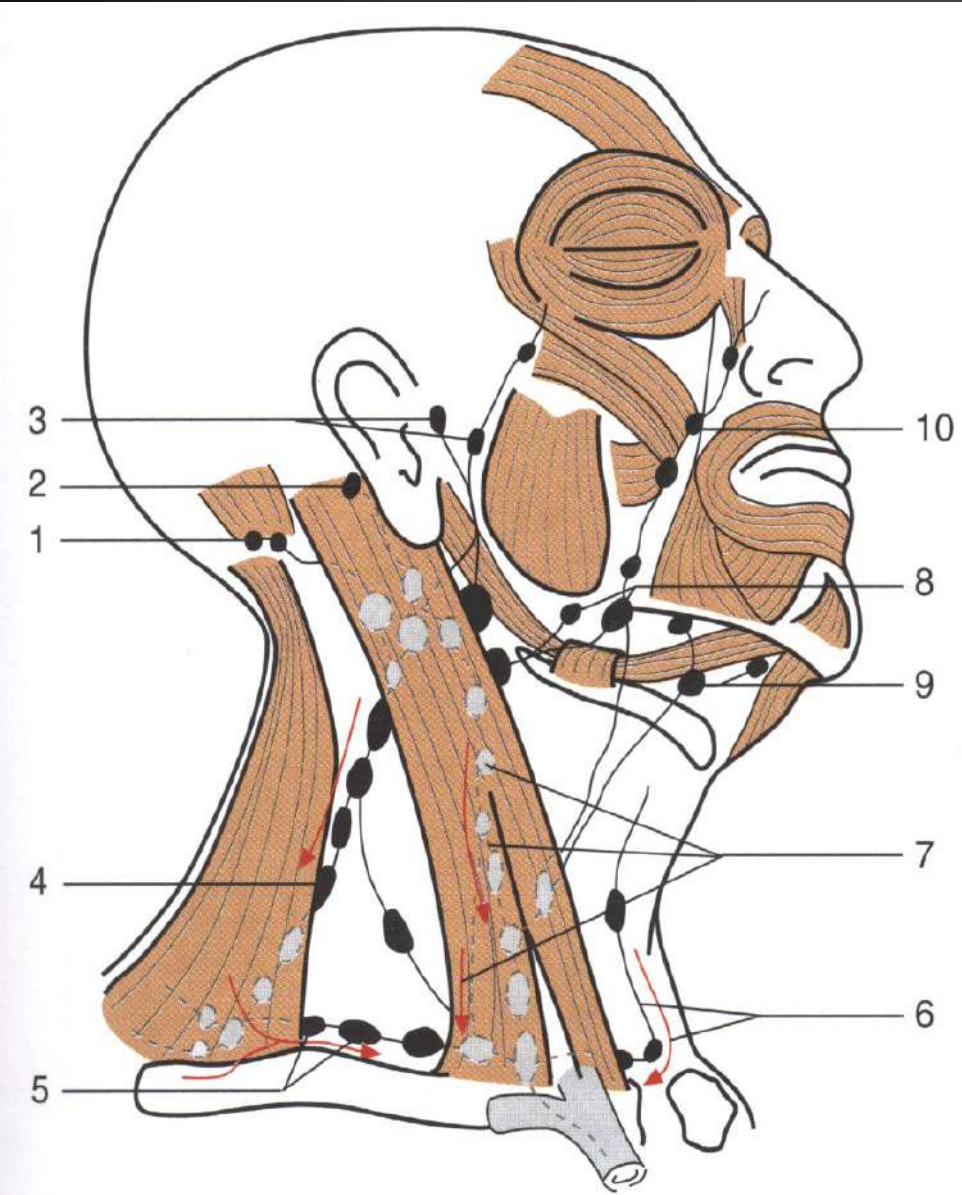




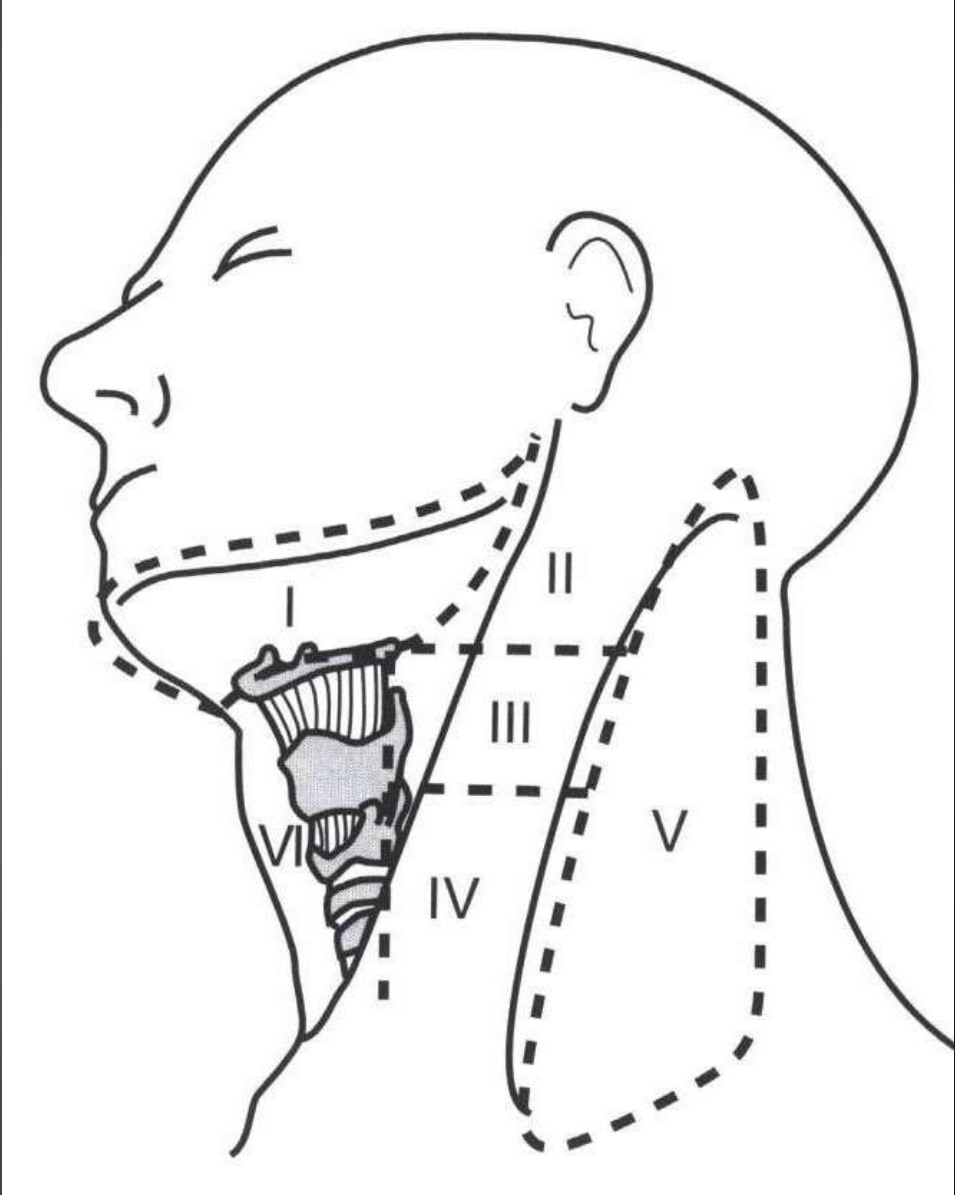
#CommittedToTheGame



Ultrasound of the neck in 7 sweeps

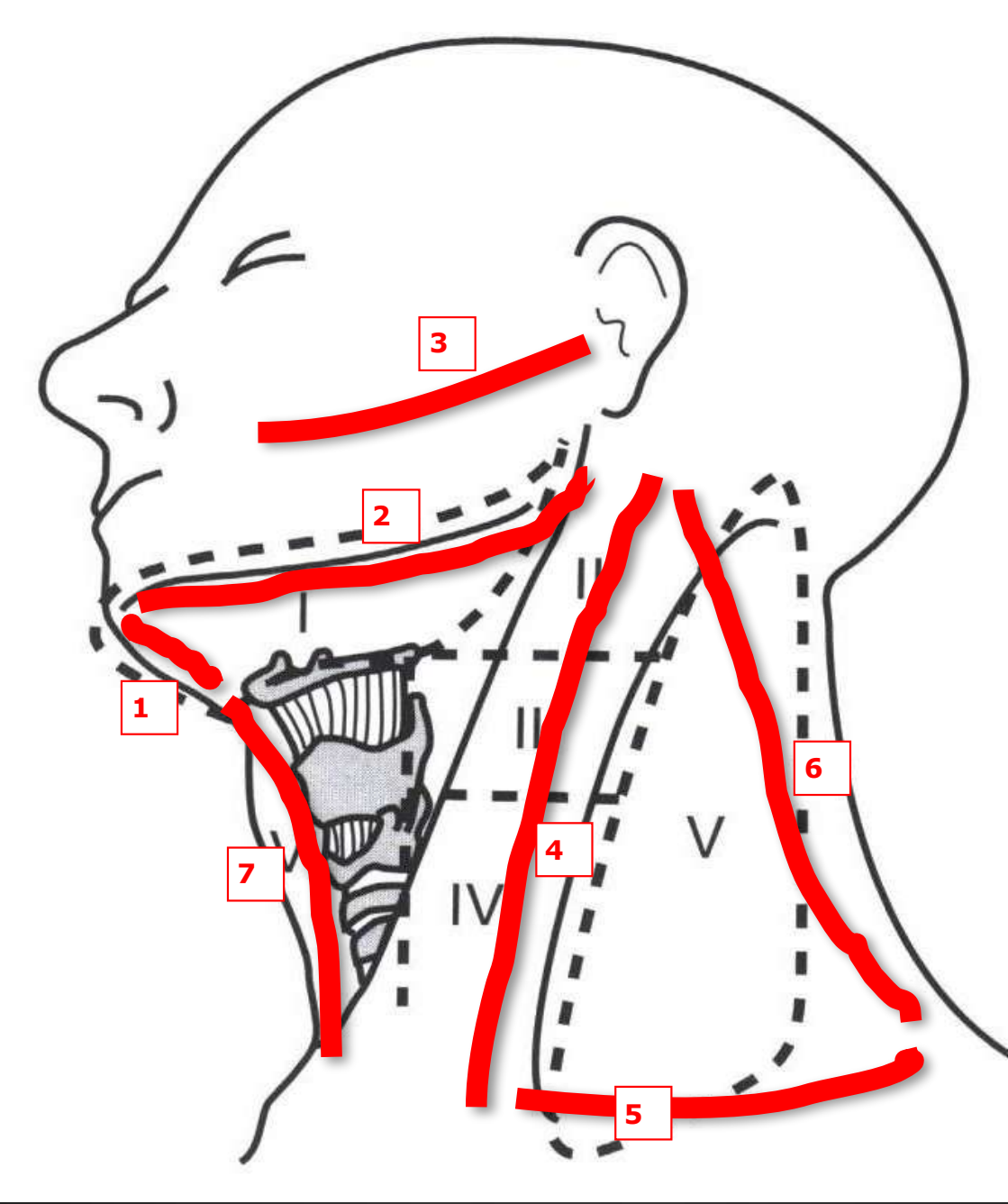


Rouviere

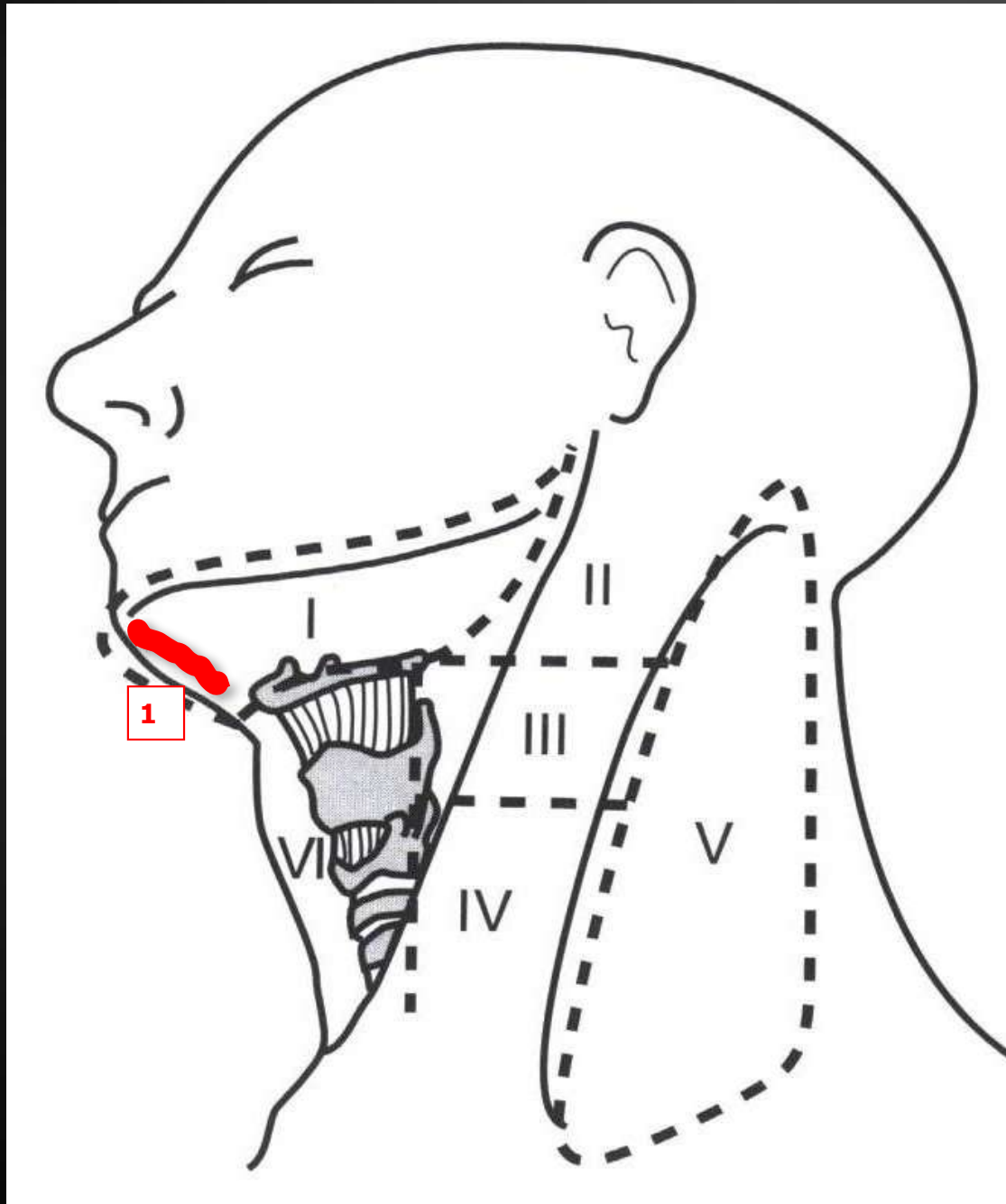


AJCC

Ultrasound of the neck in 7 sweeps

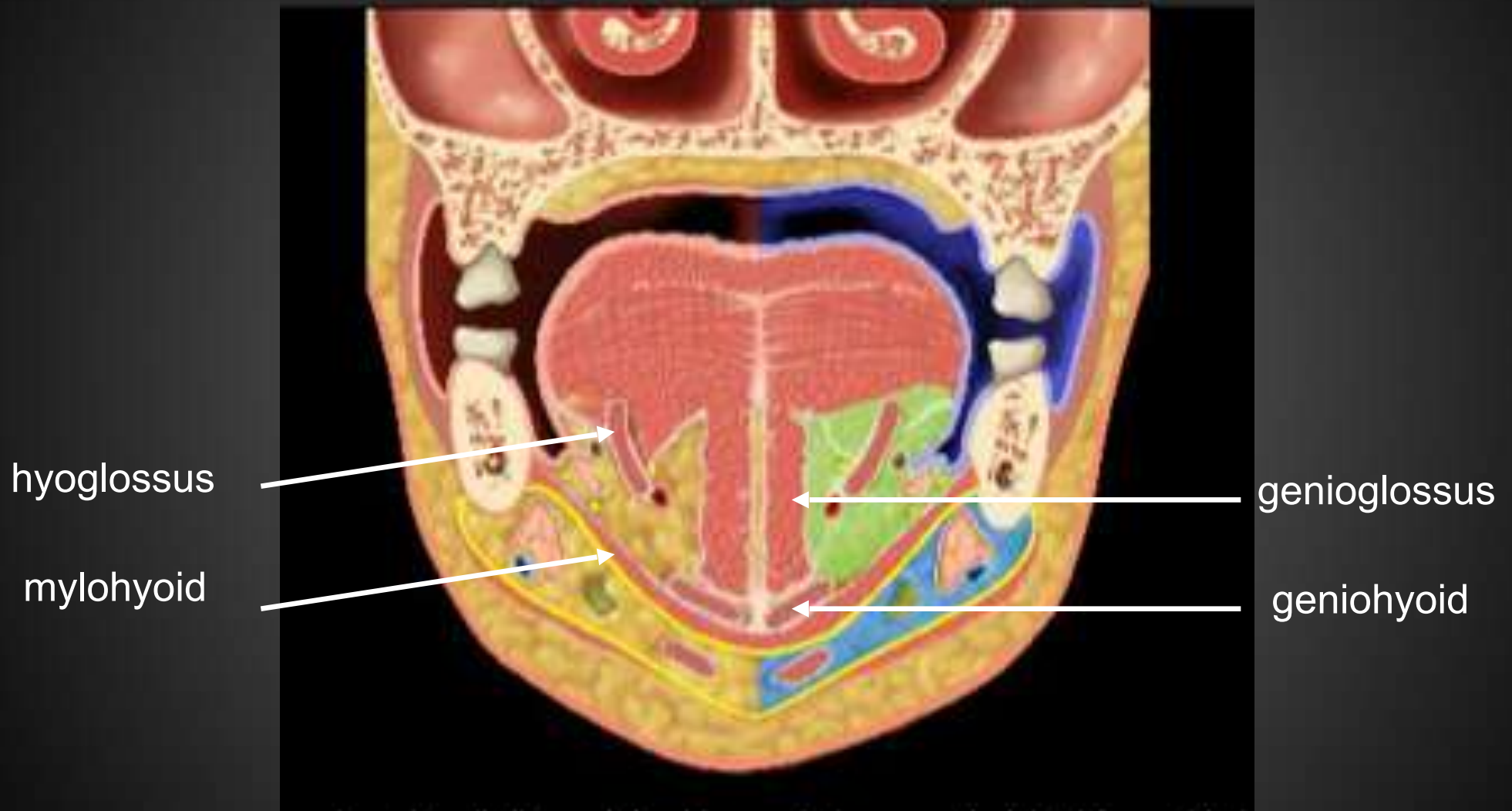


Sweep 1: submental

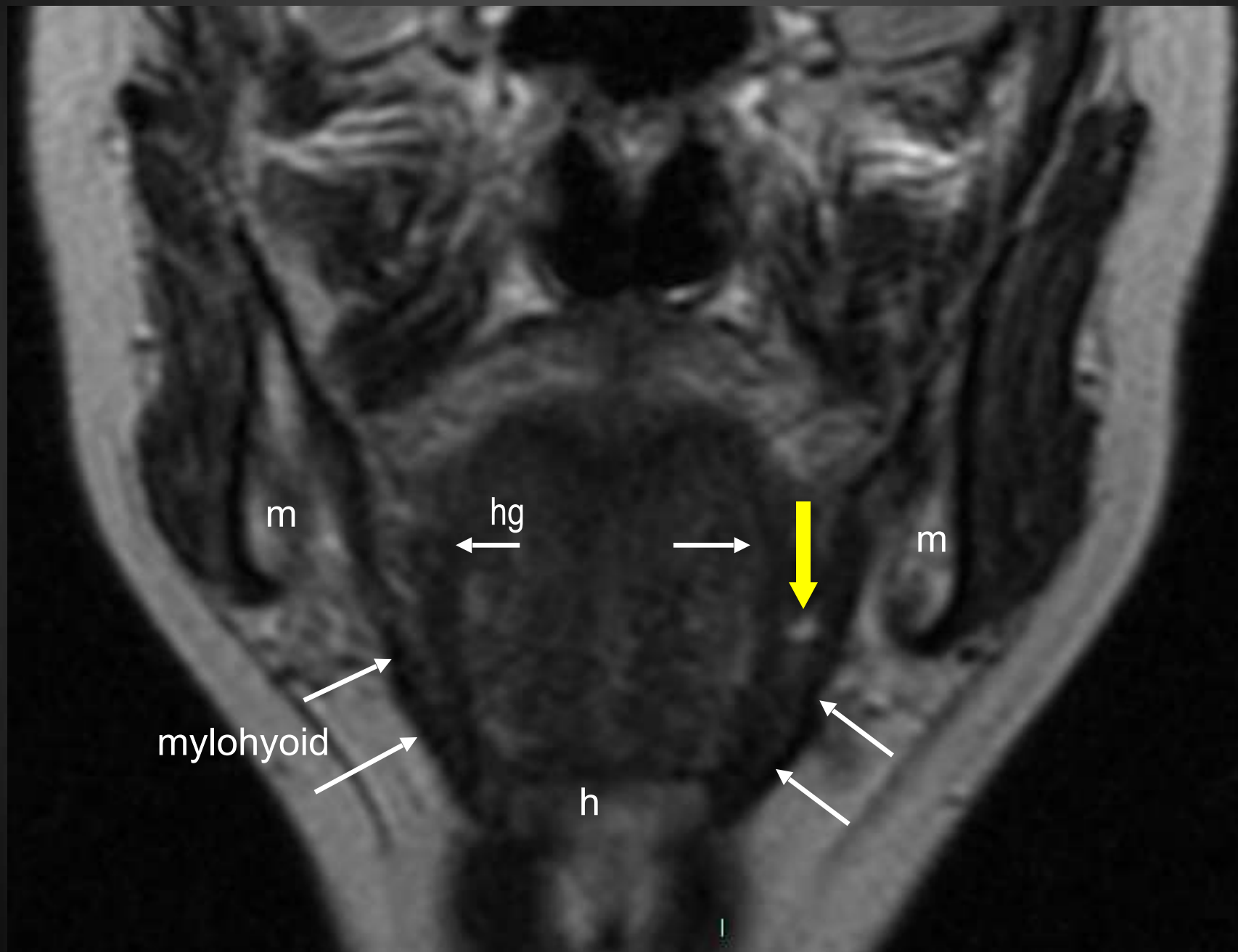


- chin to hyoid
- midline

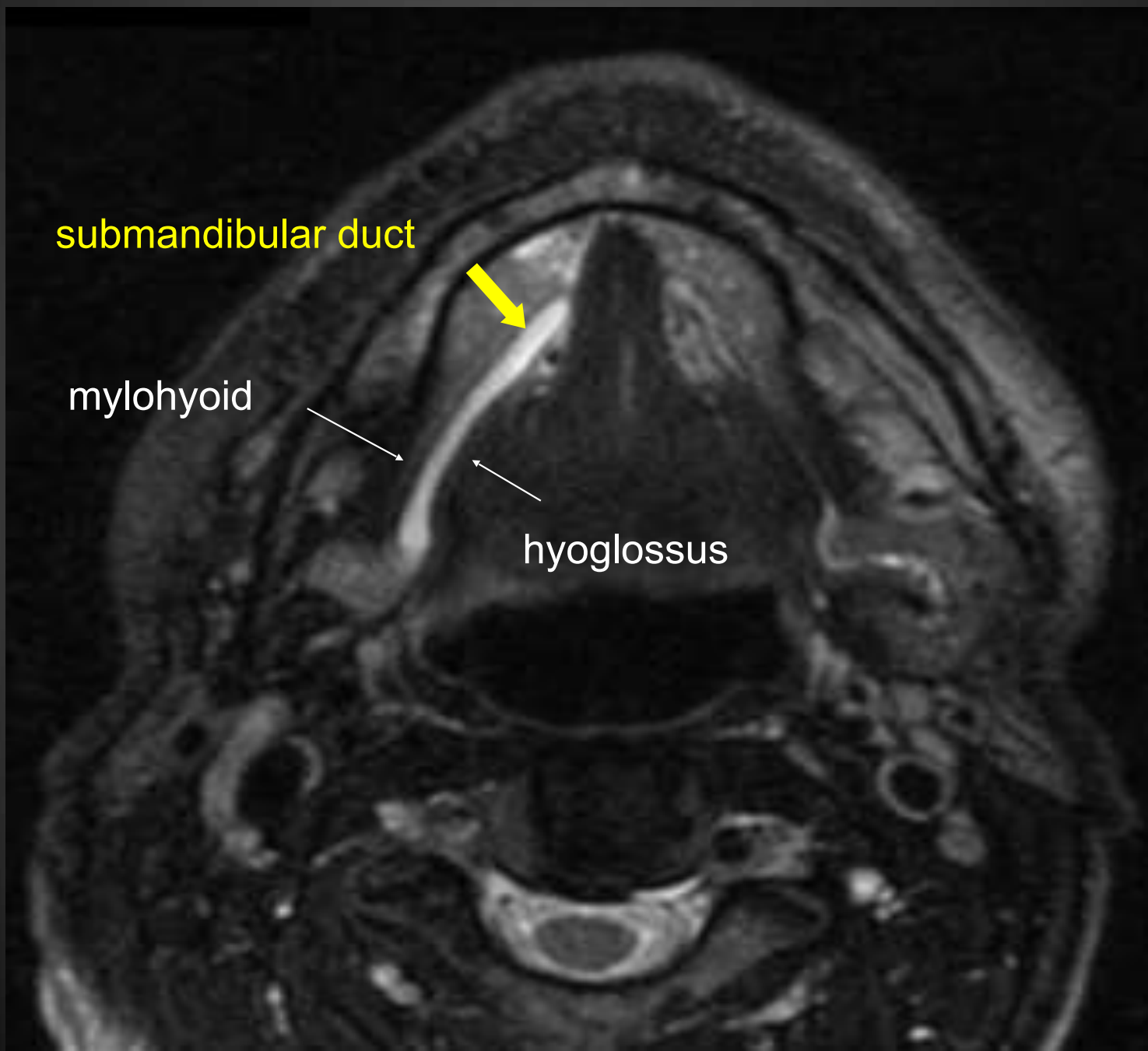
Sweep 1: submental



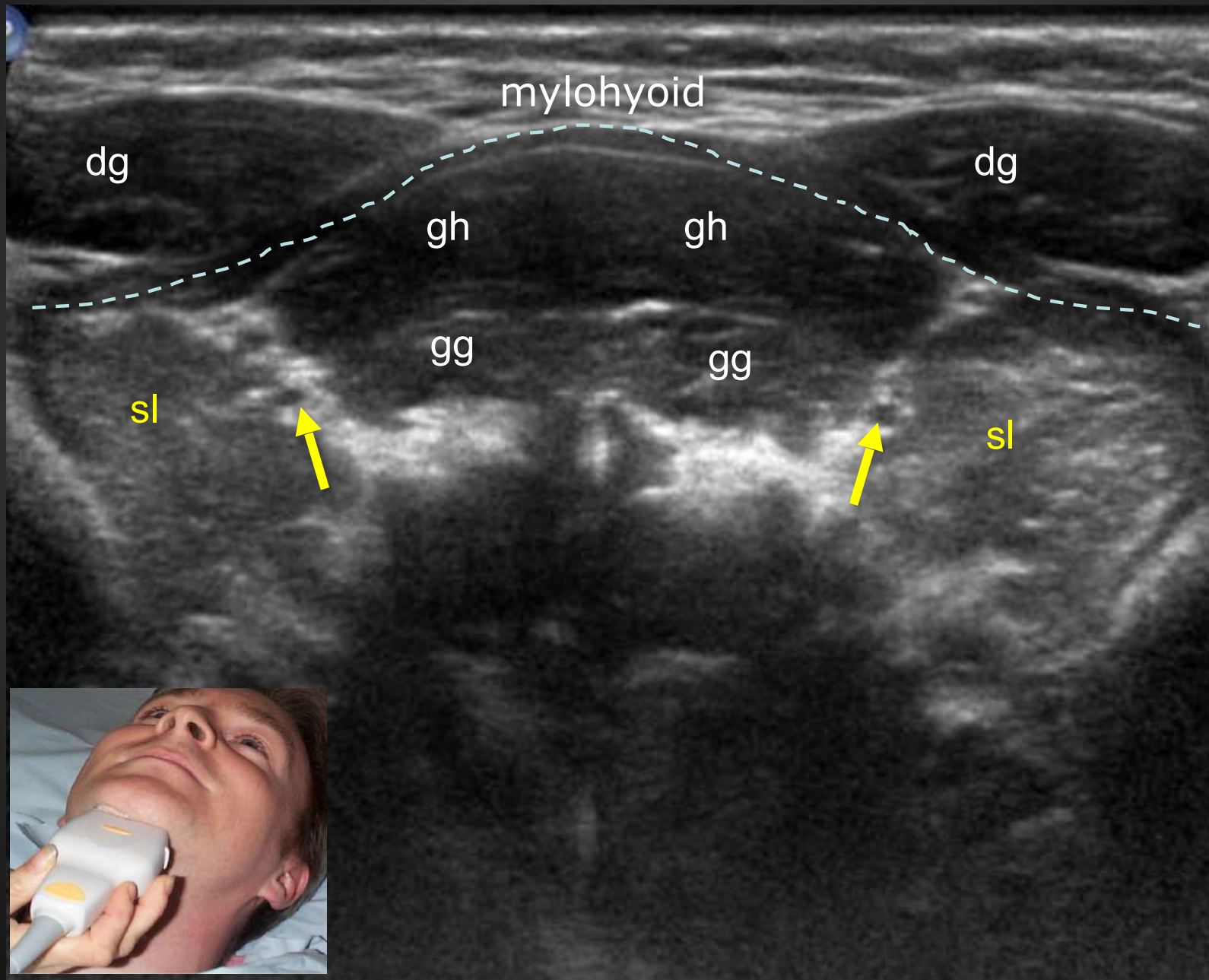
Sweep 1: submental



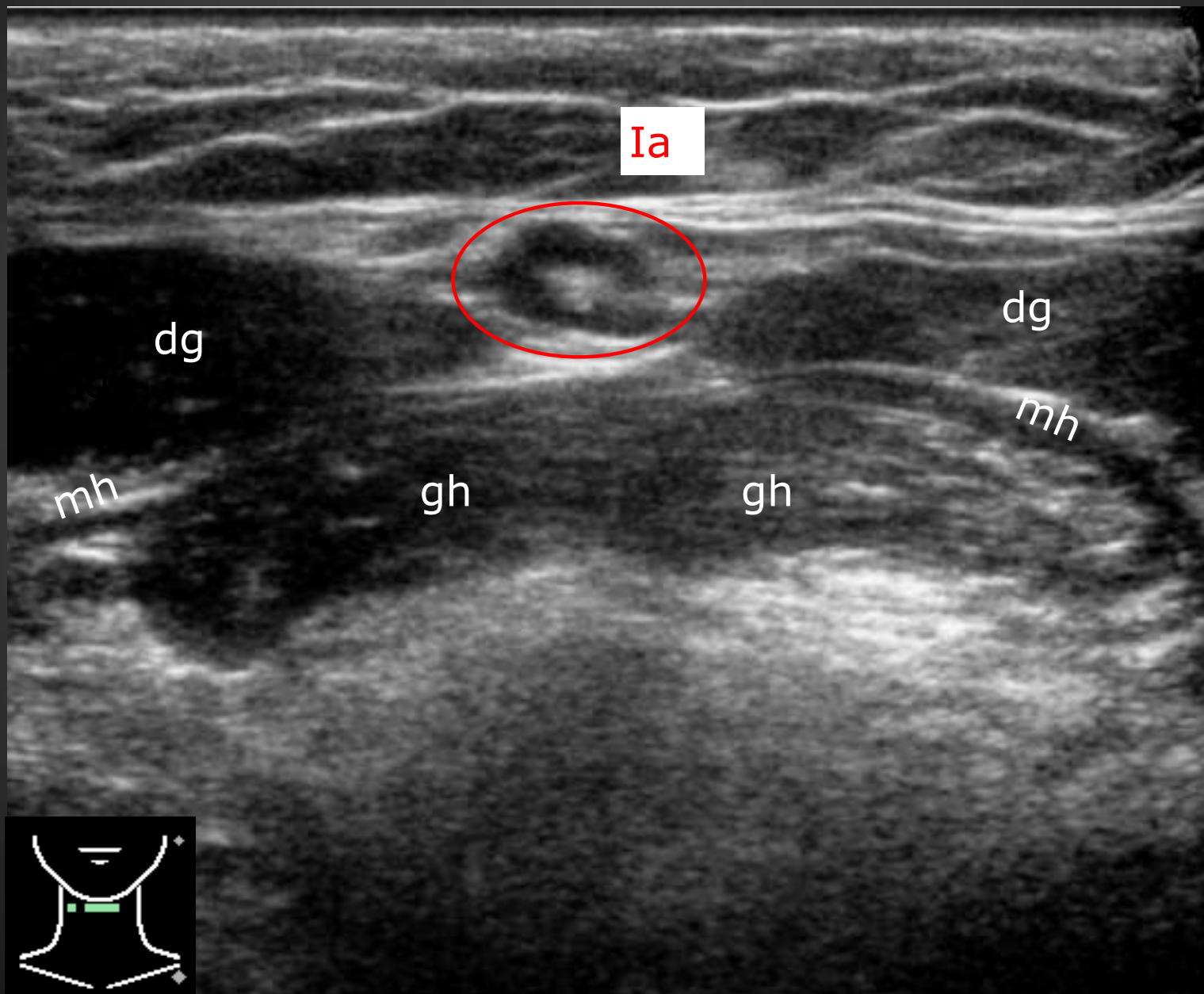
Sweep 1: submental



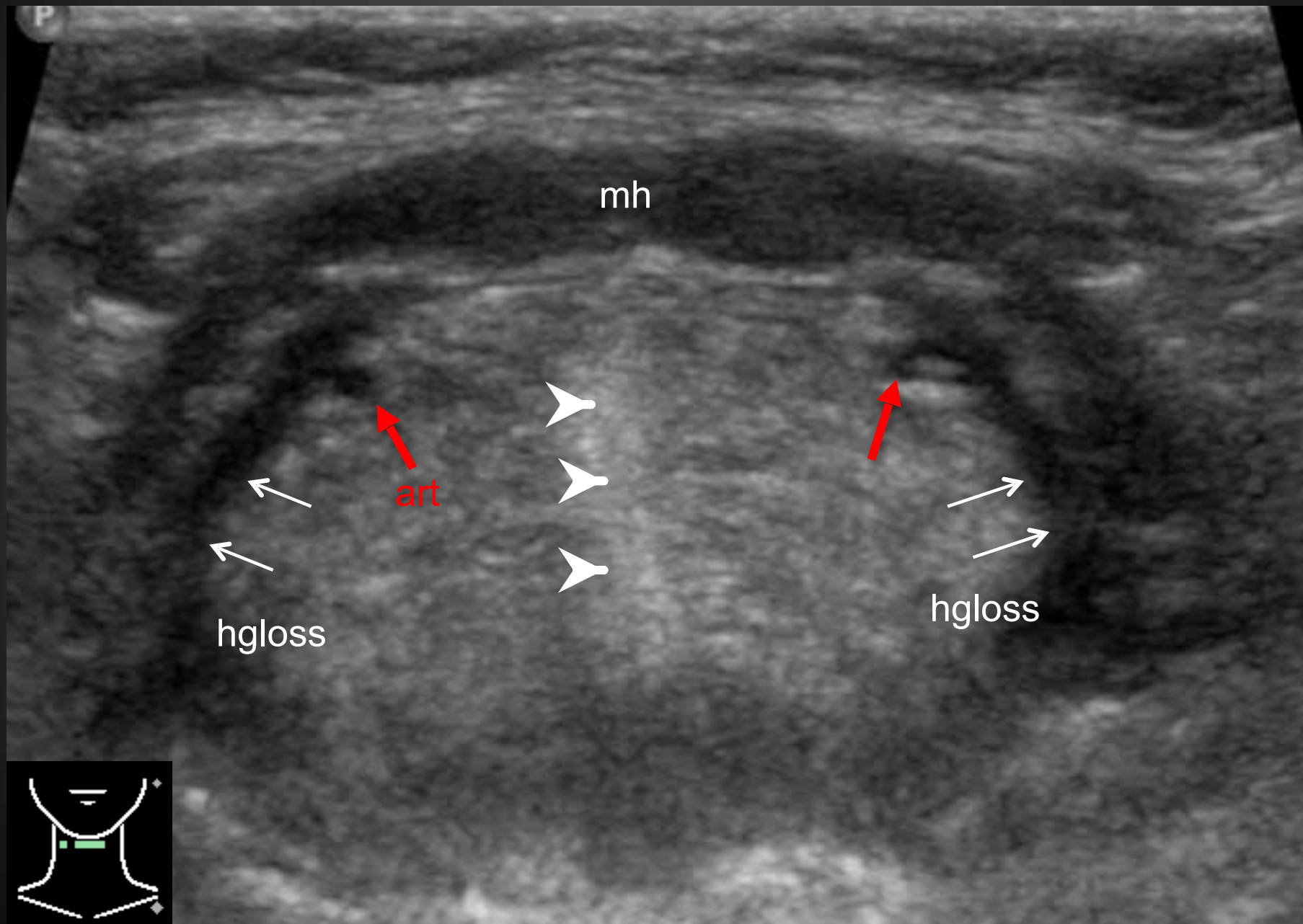
Sweep 1: submental



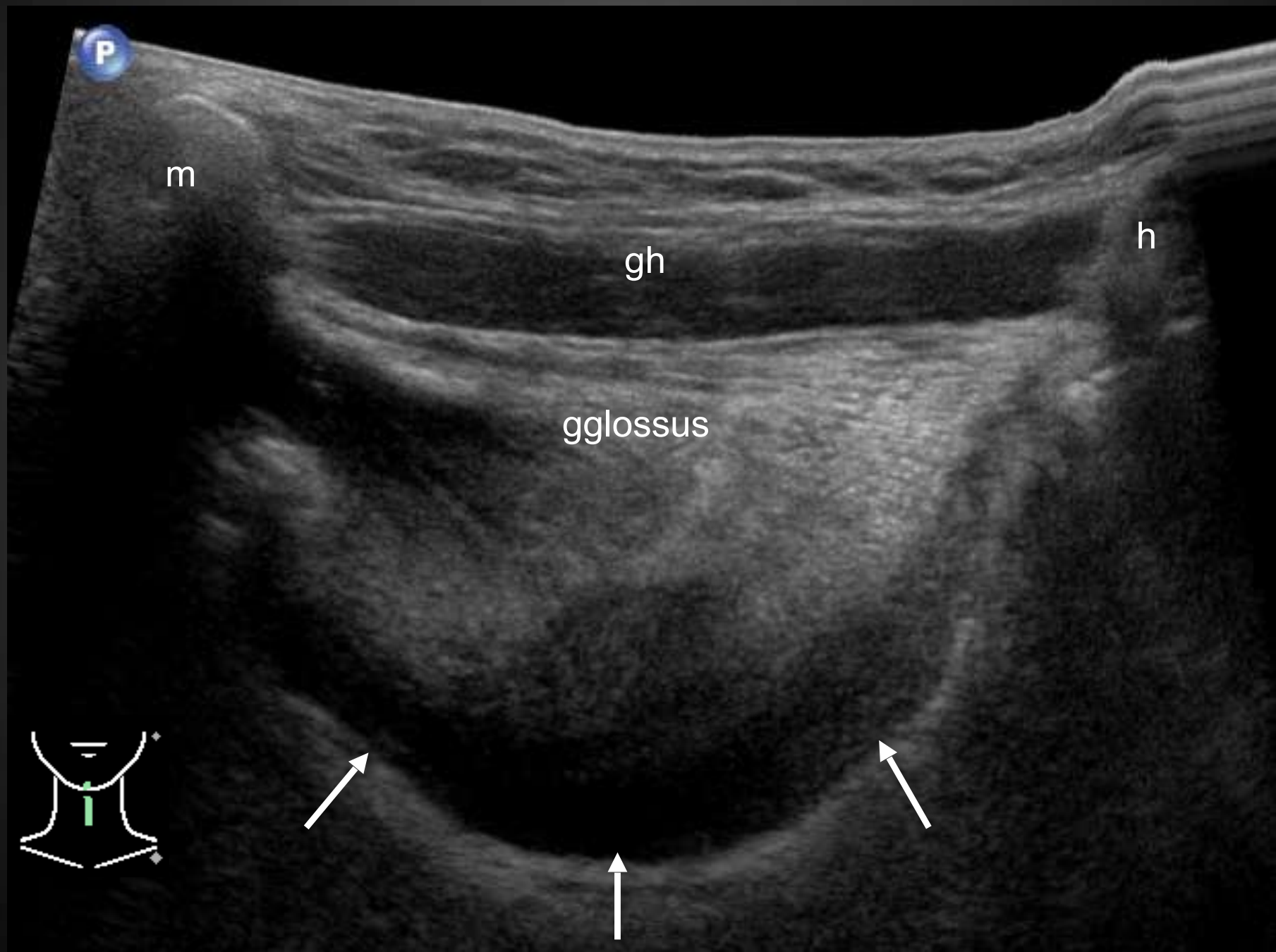
Sweep 1: submental



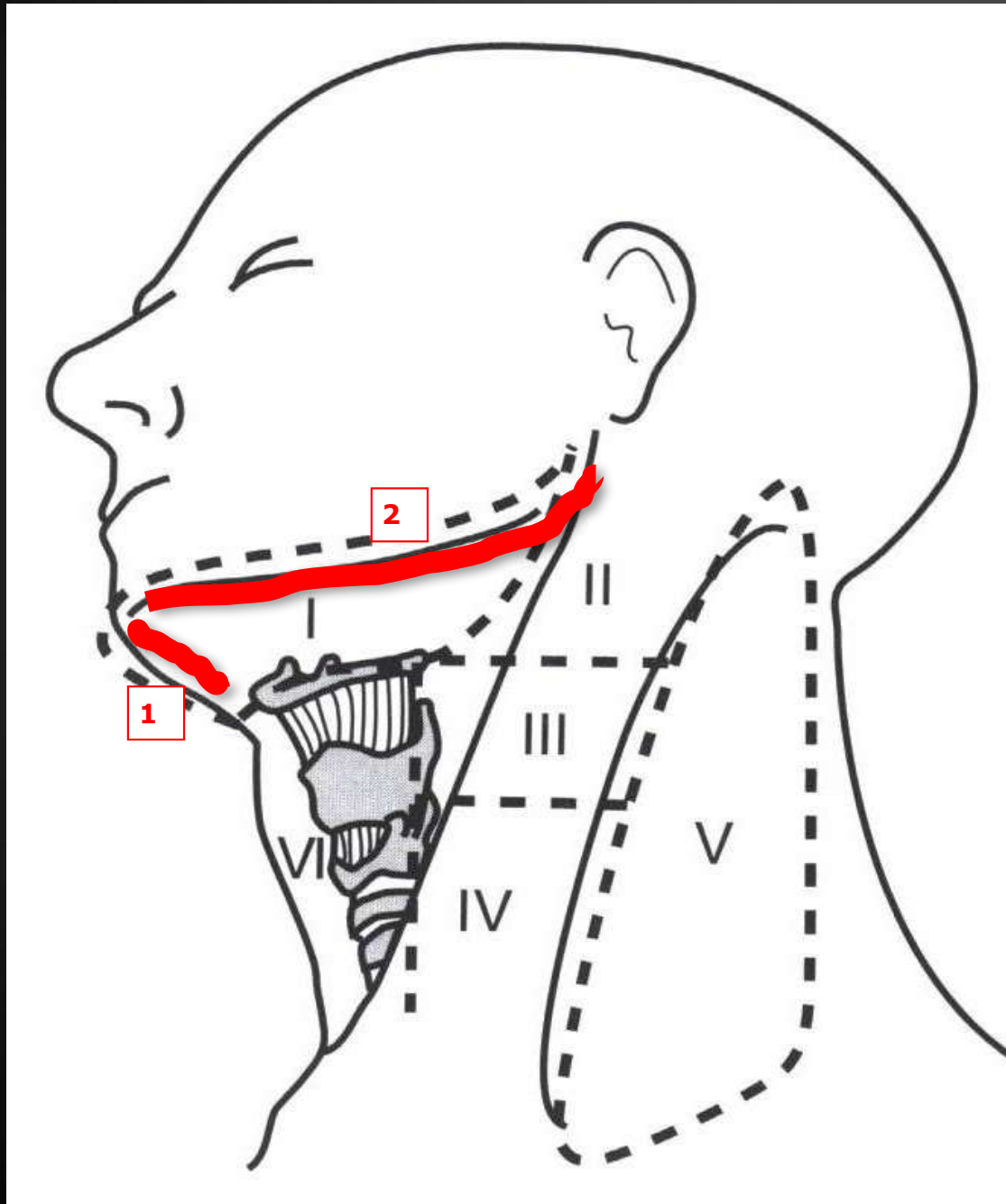
Sweep 1: submental



Sweep 1: submental

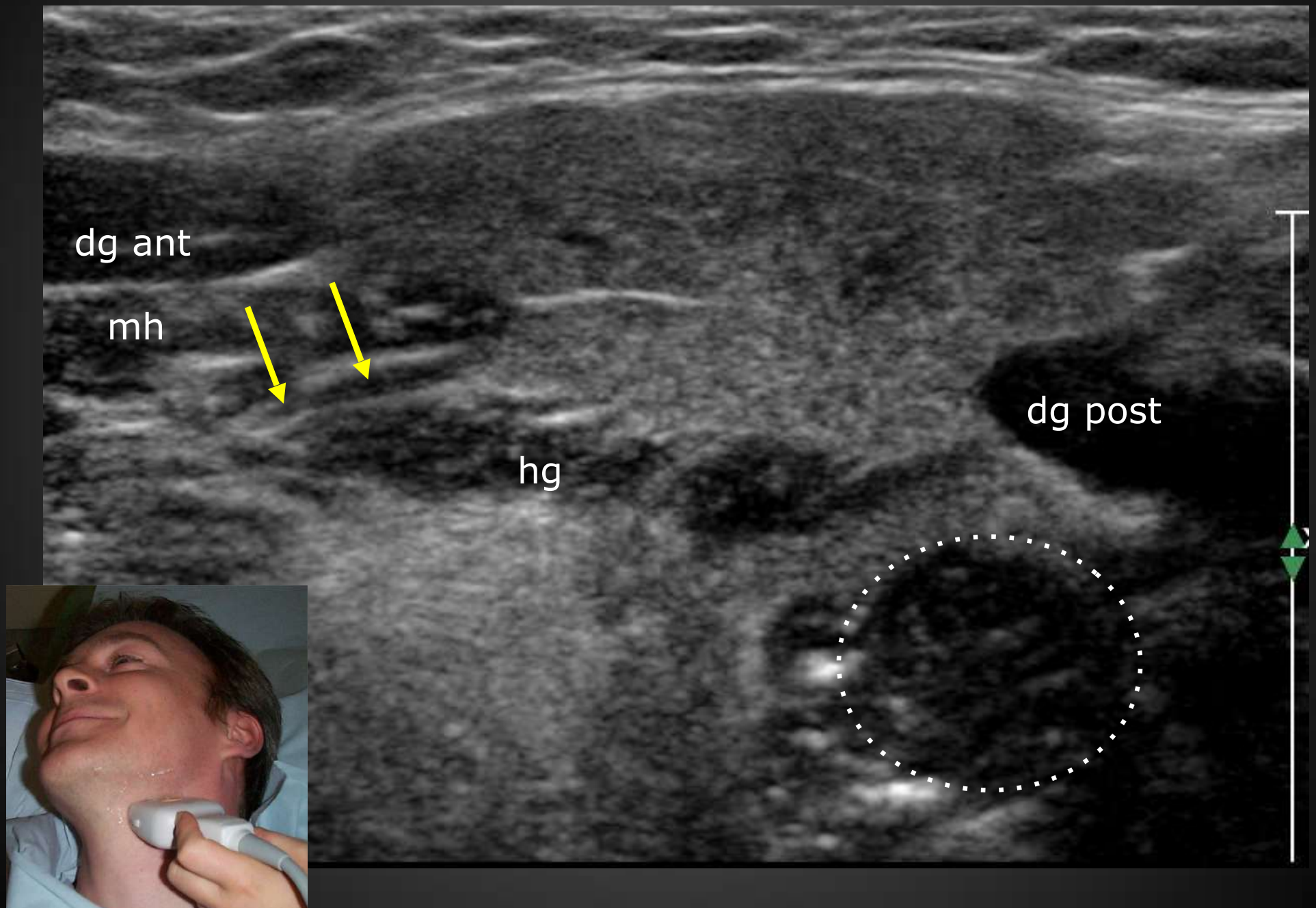


Sweep 2: submandibular

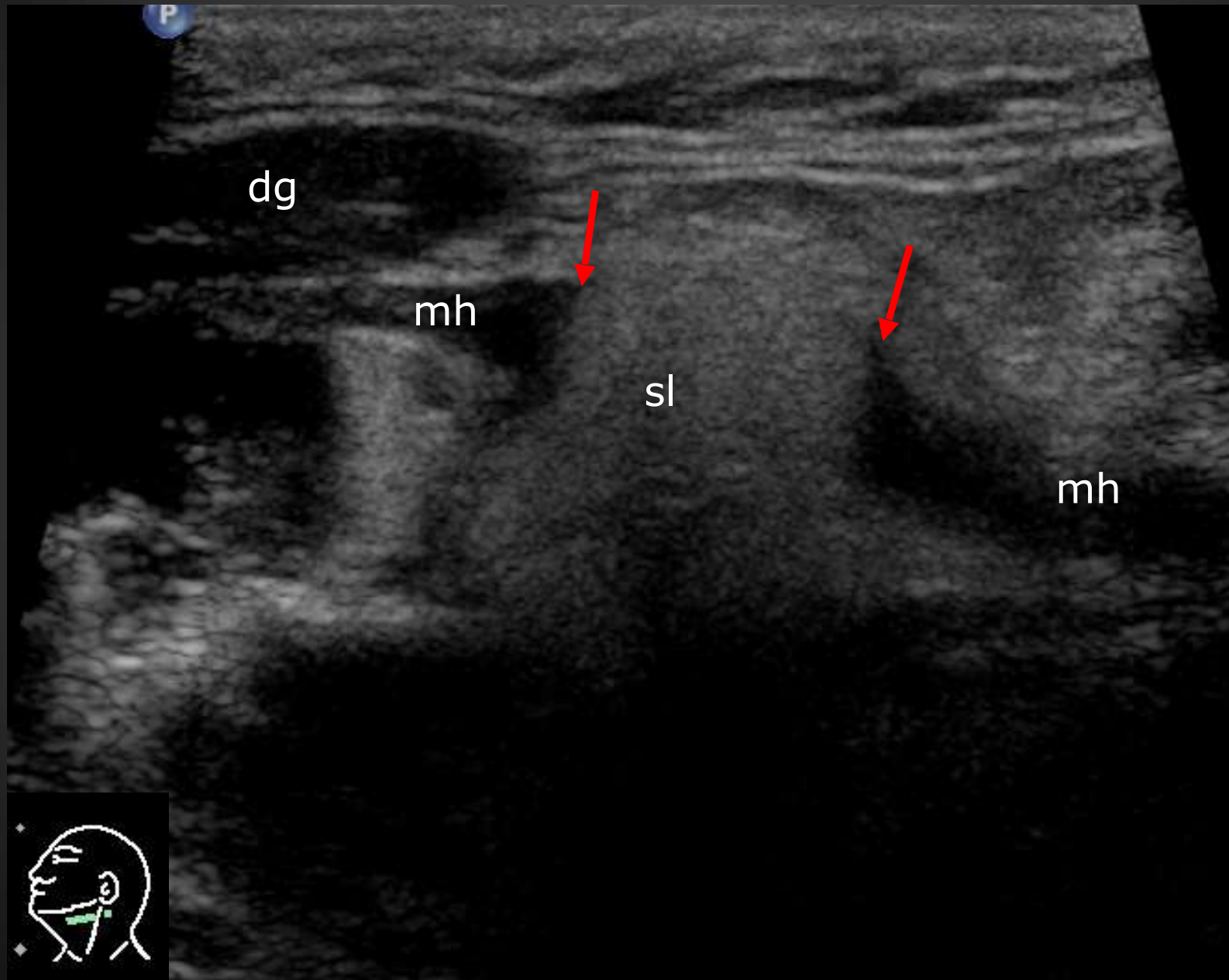


- Chin to angle of mandible
- Follow mylohyoid

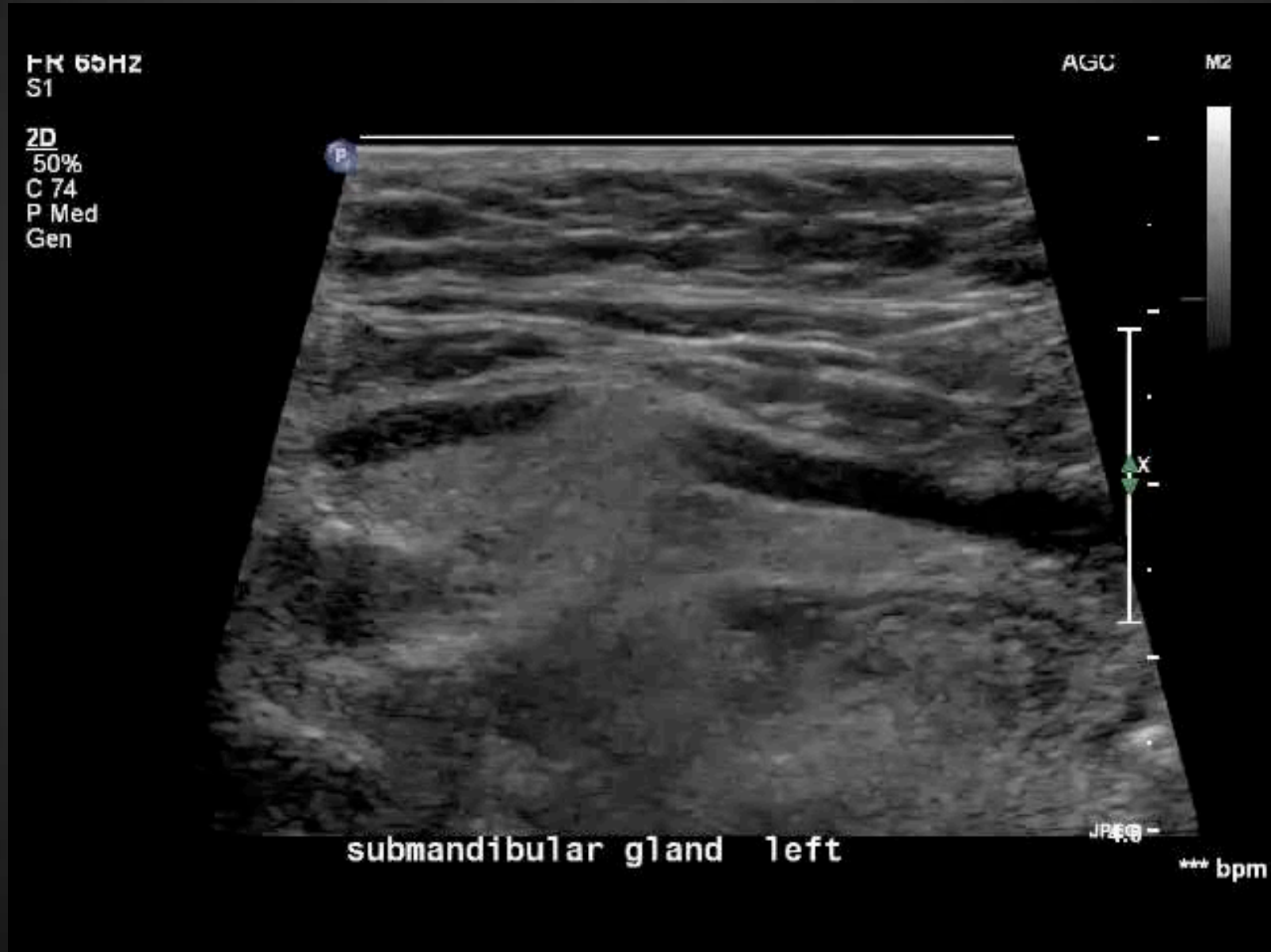Sweep 2: submandibular



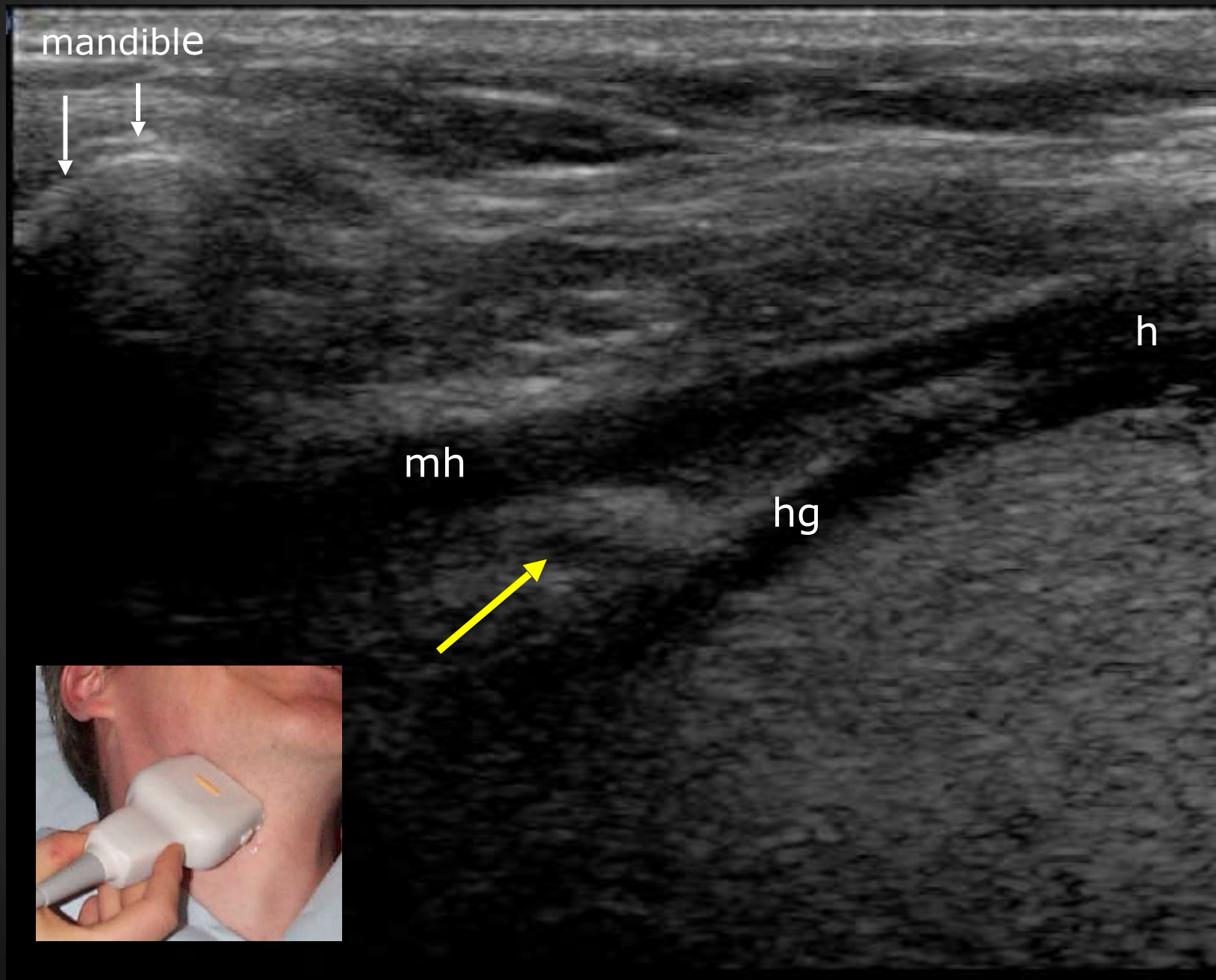
Sweep 2: submandibular



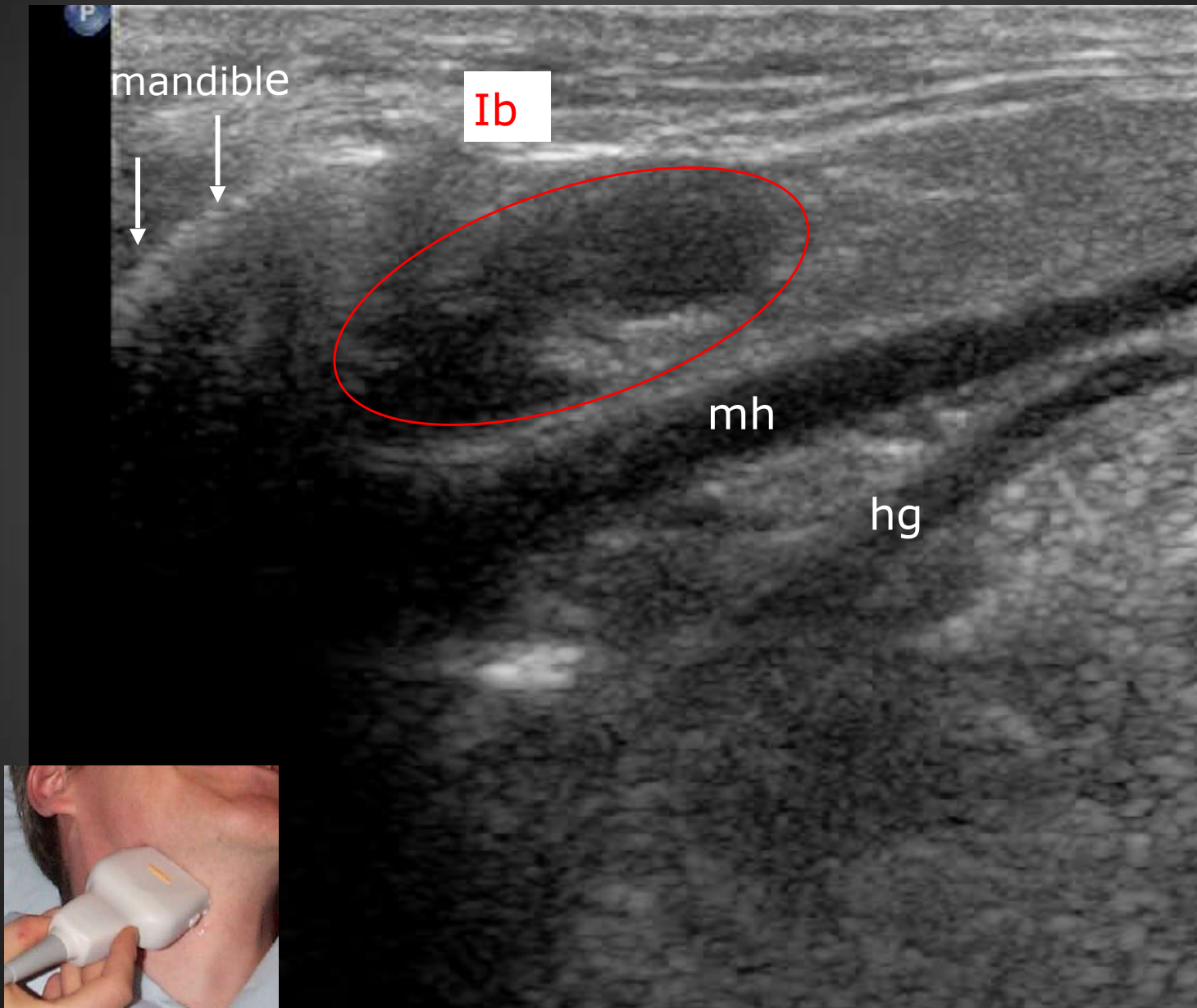
Sweep 2: submandibular



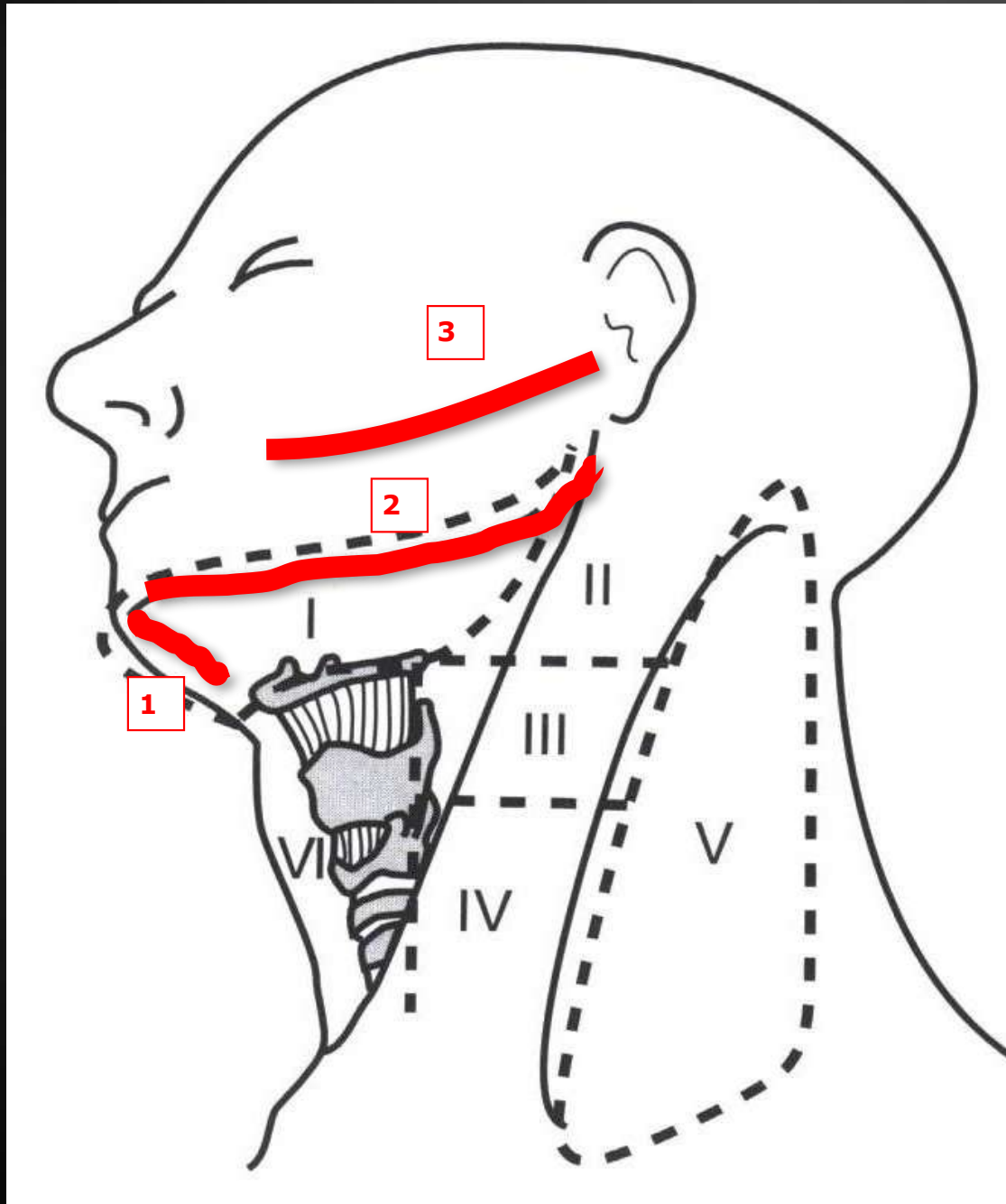
Sweep 2: submandibular



Sweep 2: submandibular

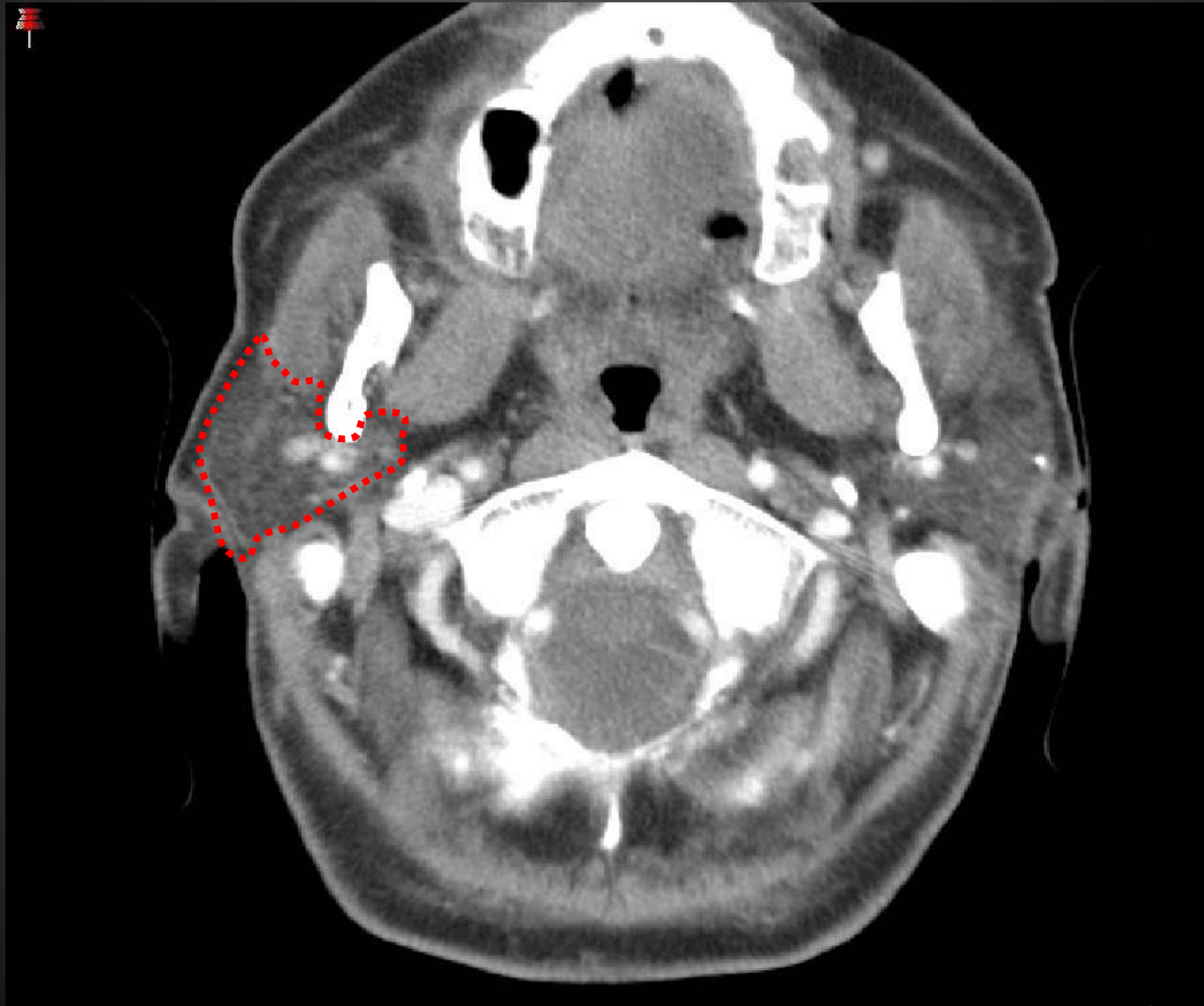

Sweep 3: parotid

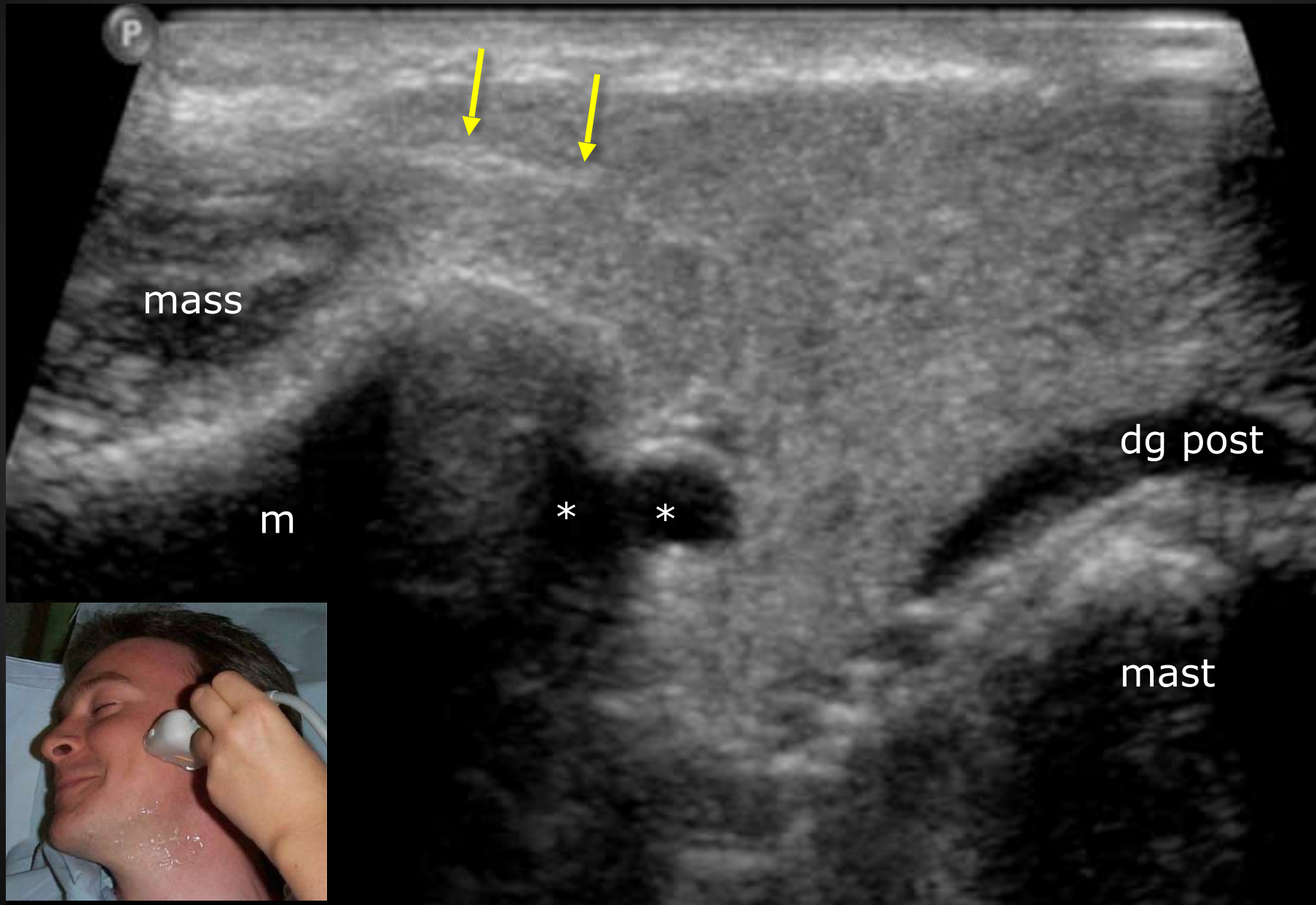


- EAM to angle of mouth
- Follow parotid duct

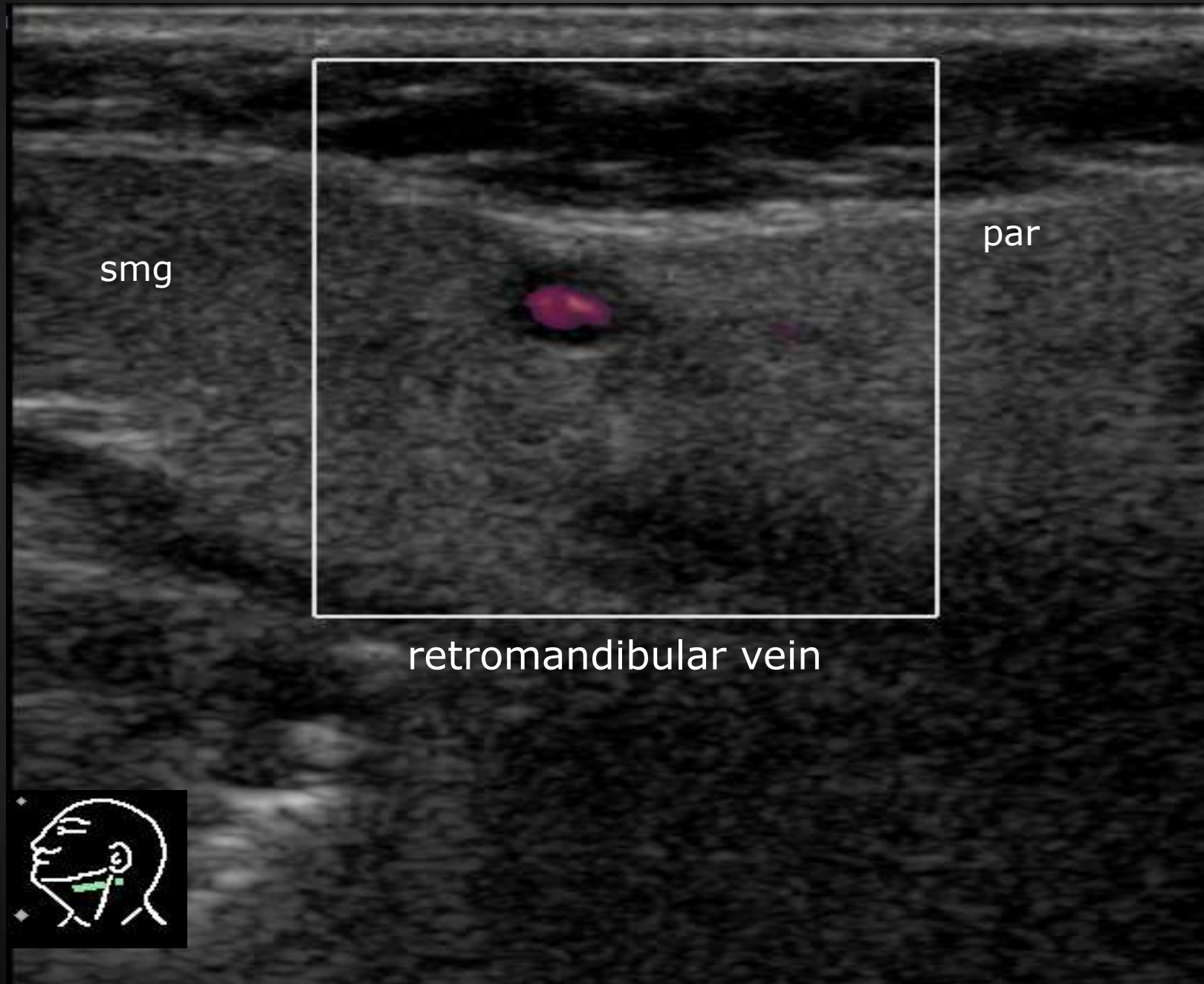
Sweep 3: parotid



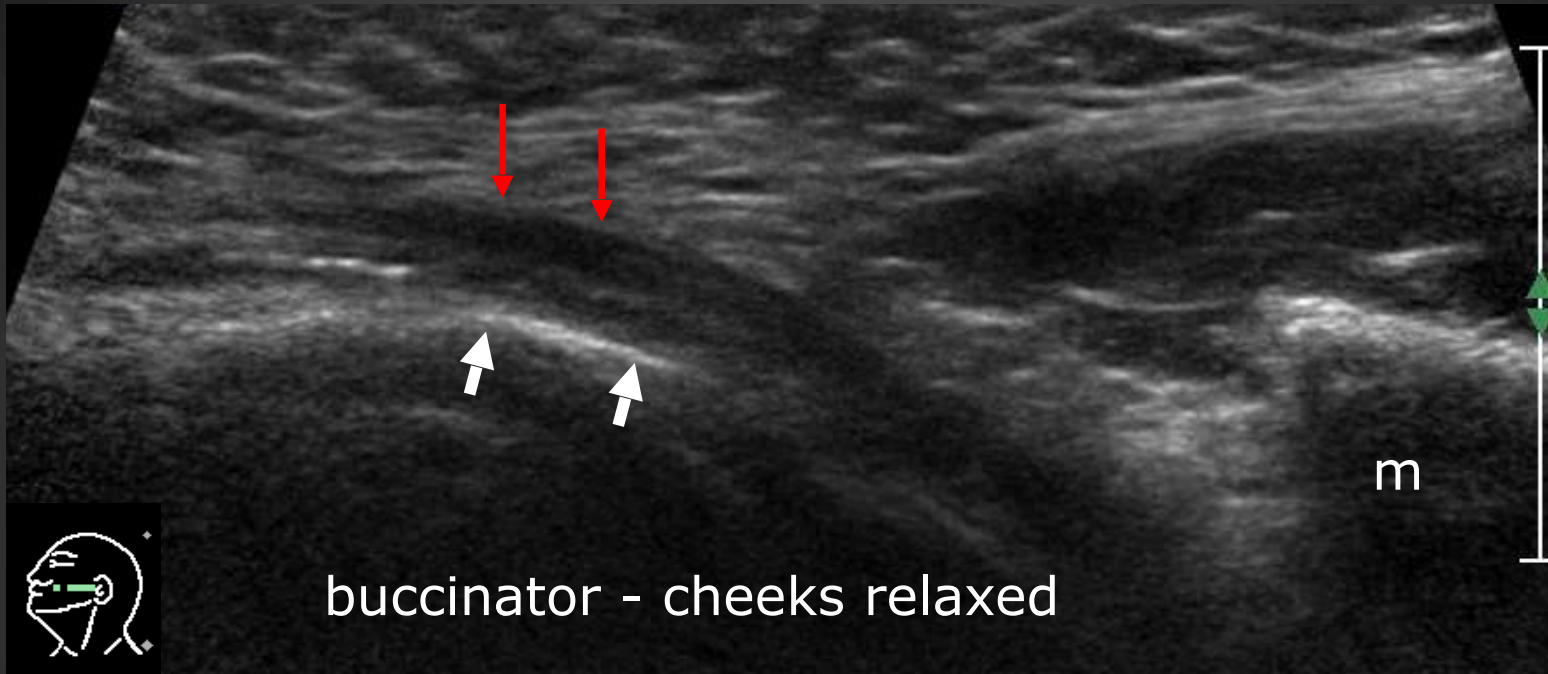
Sweep 3: parotid



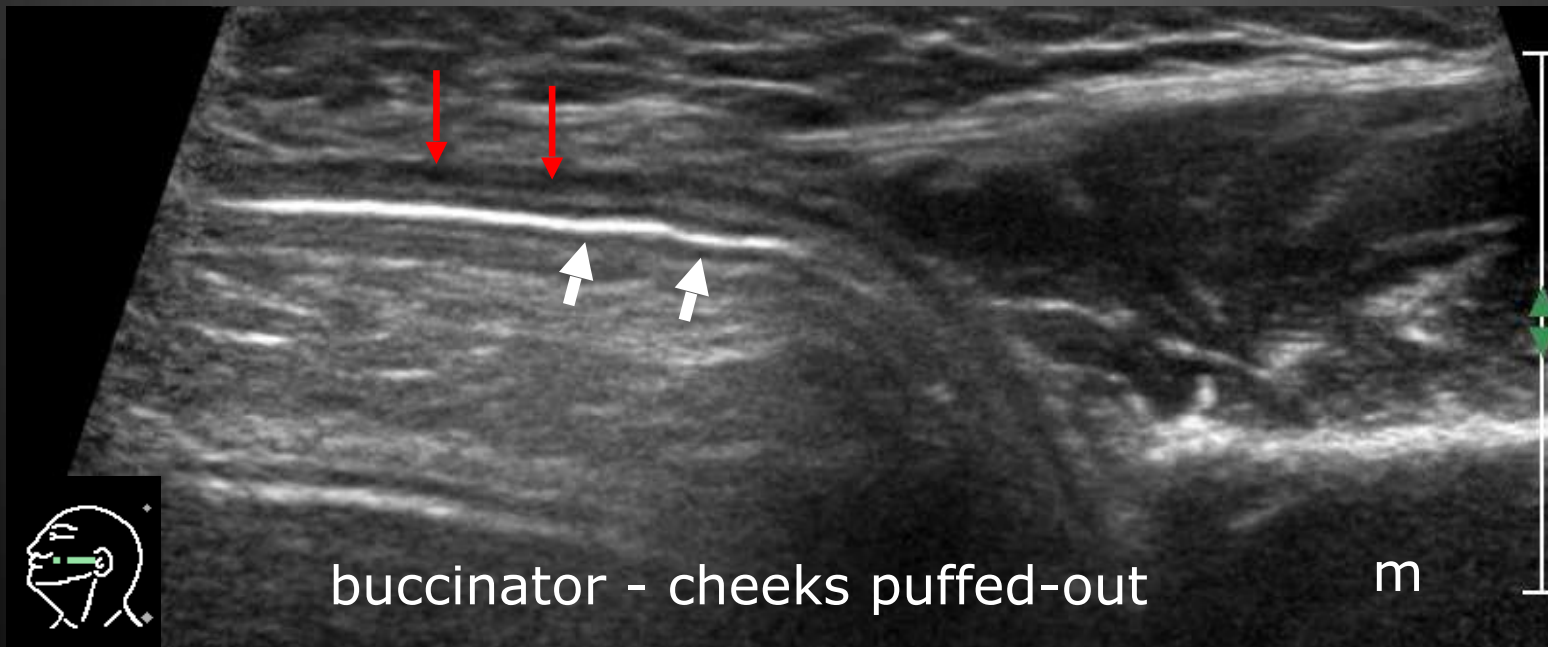
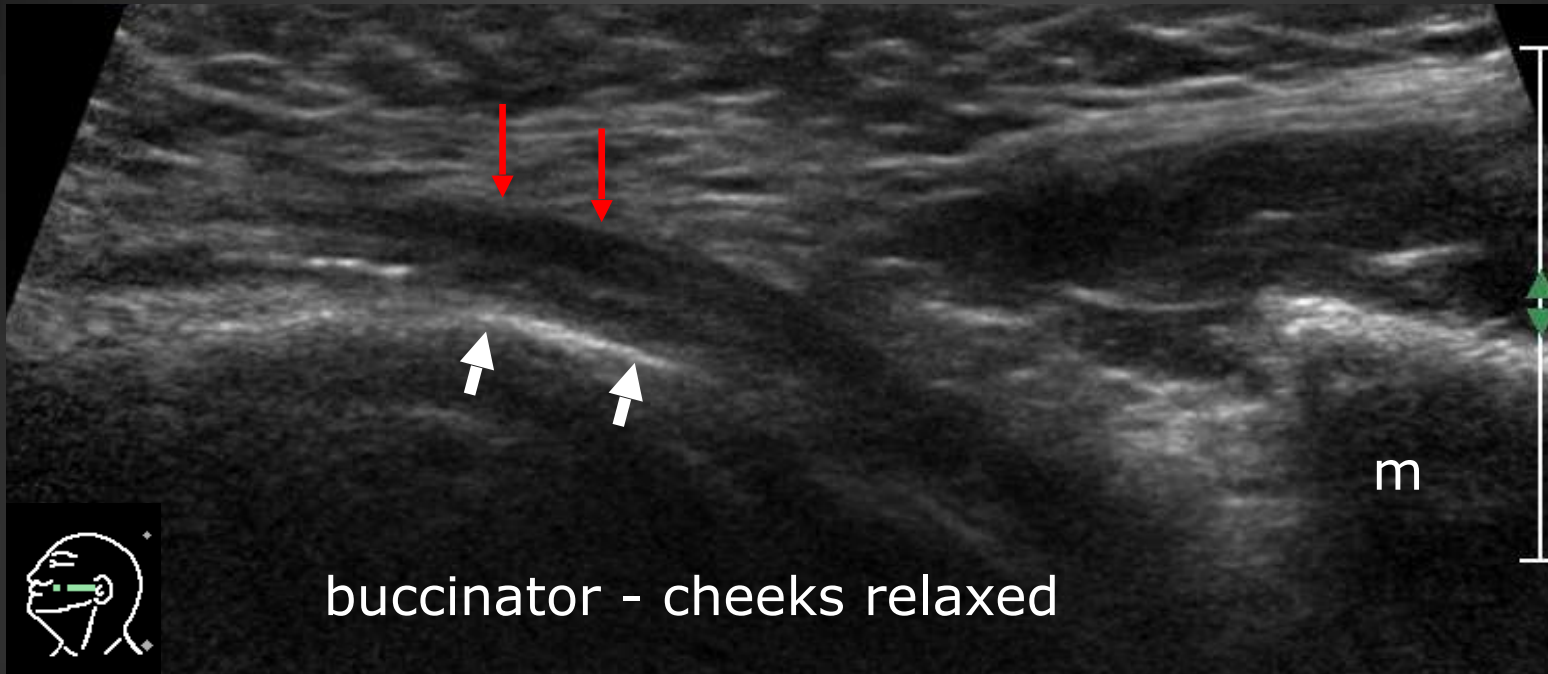
Sweep 3: parotid



Sweep 3: parotid

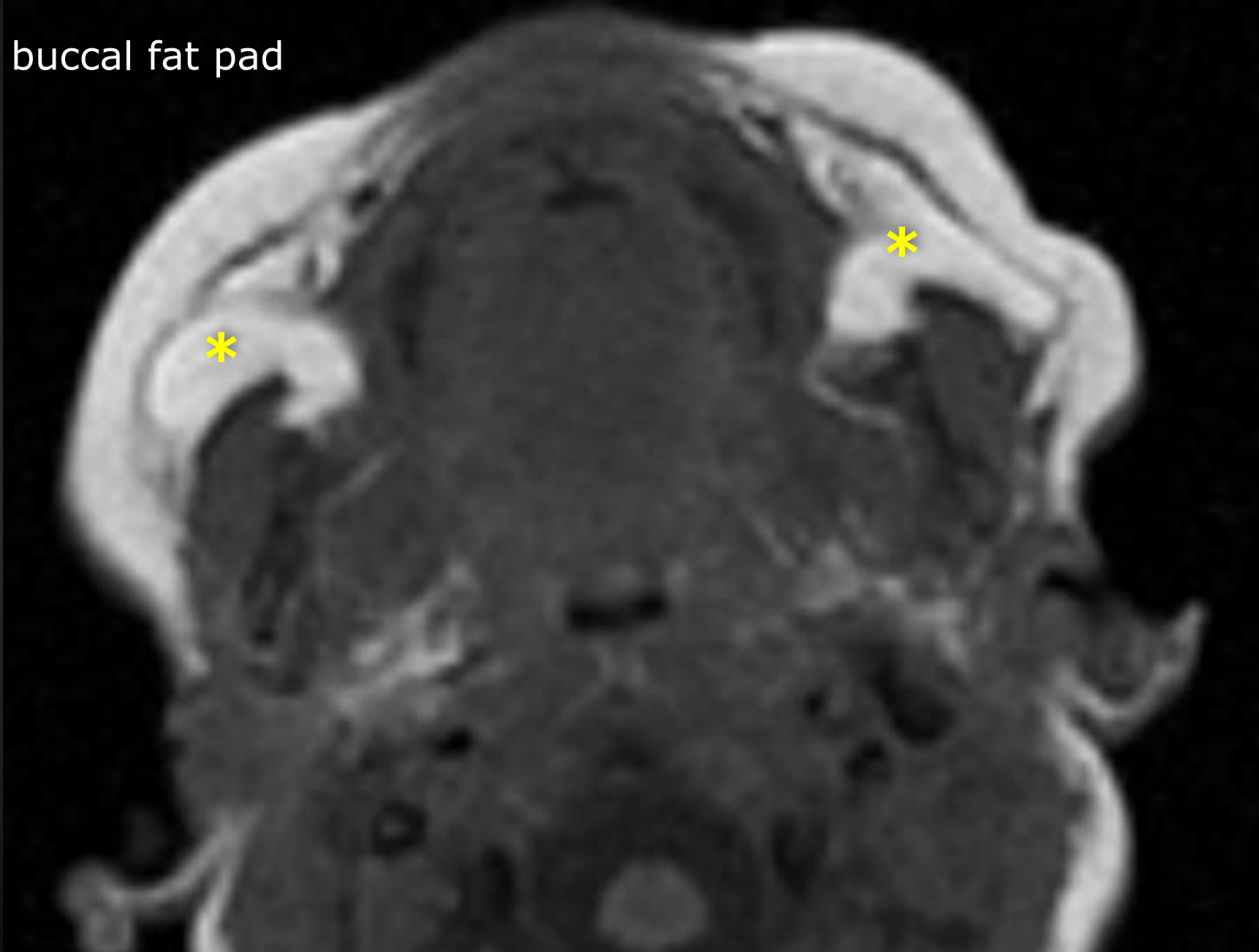


Sweep 3: parotid

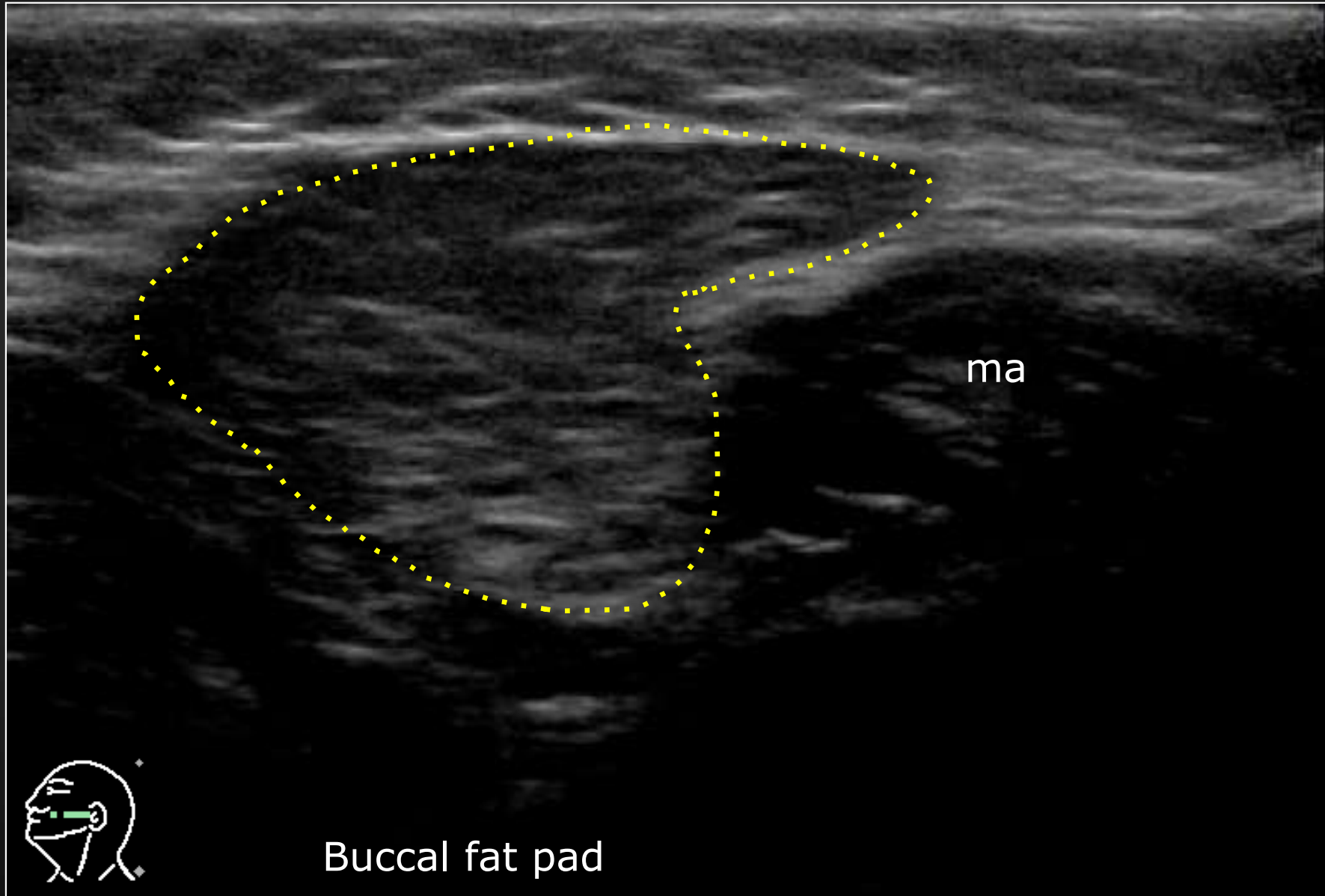


Sweep 3: parotid

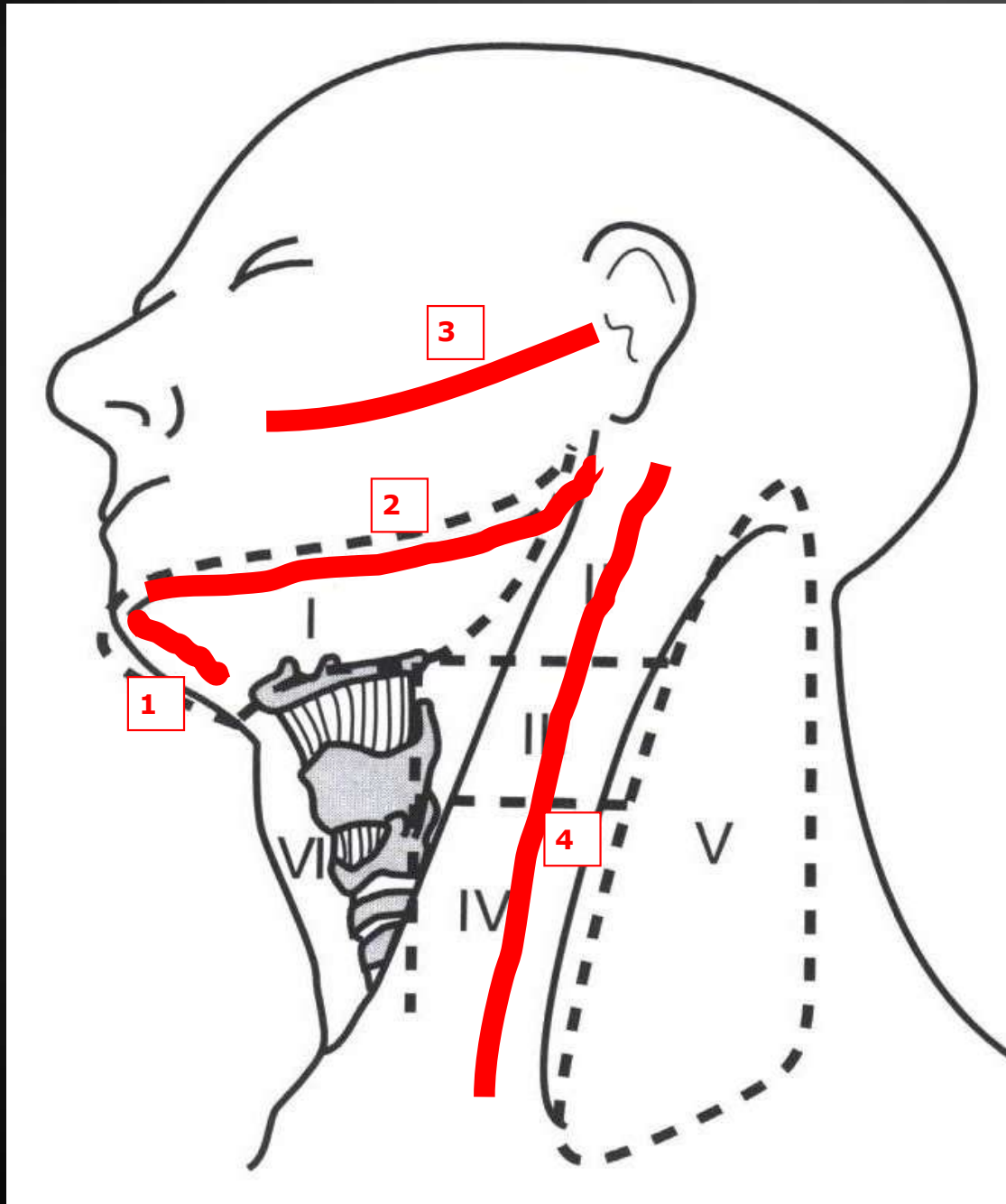
buccal fat pad



Sweep 3: parotid

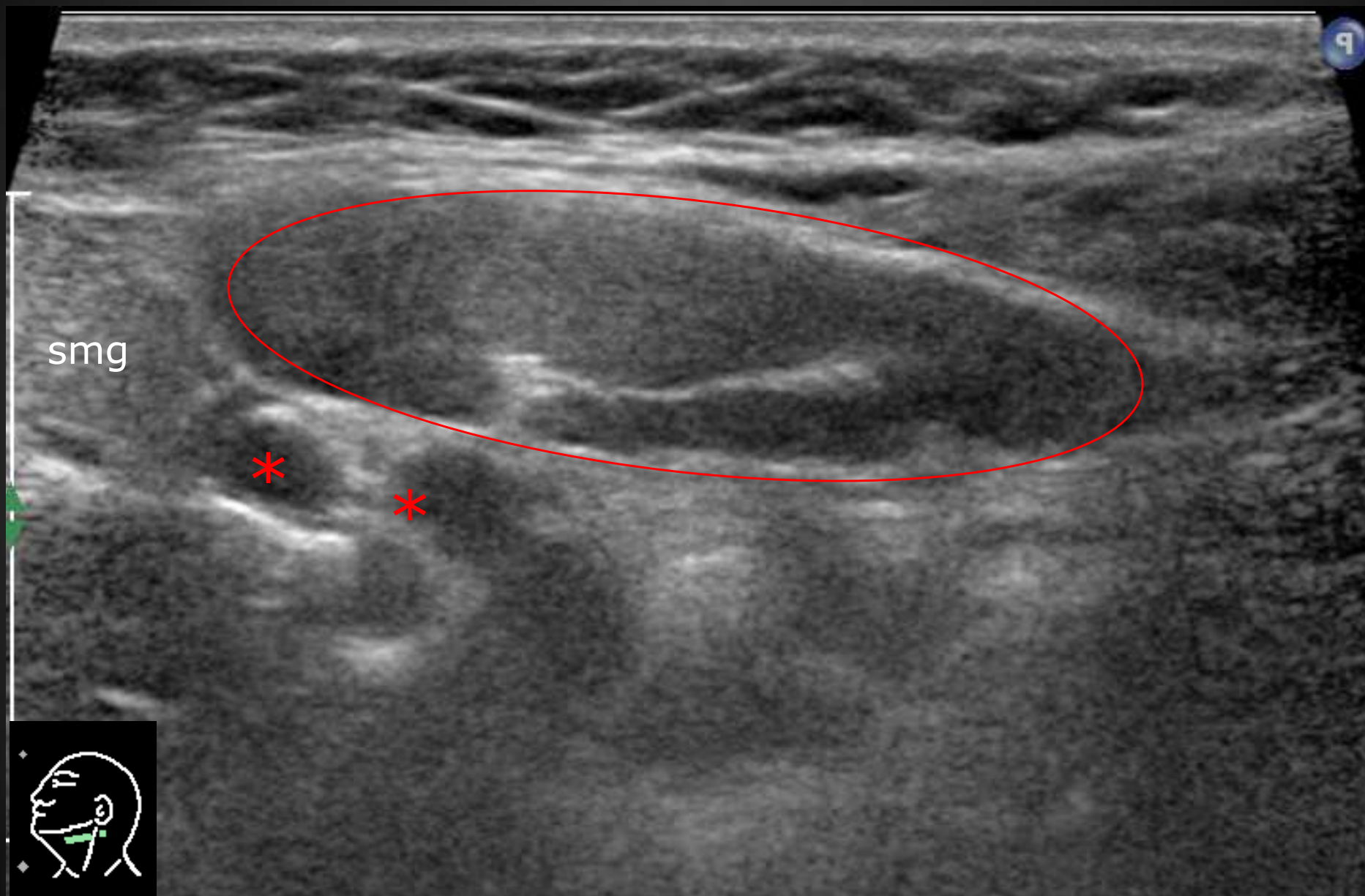


Sweep 4: deep cervical chain



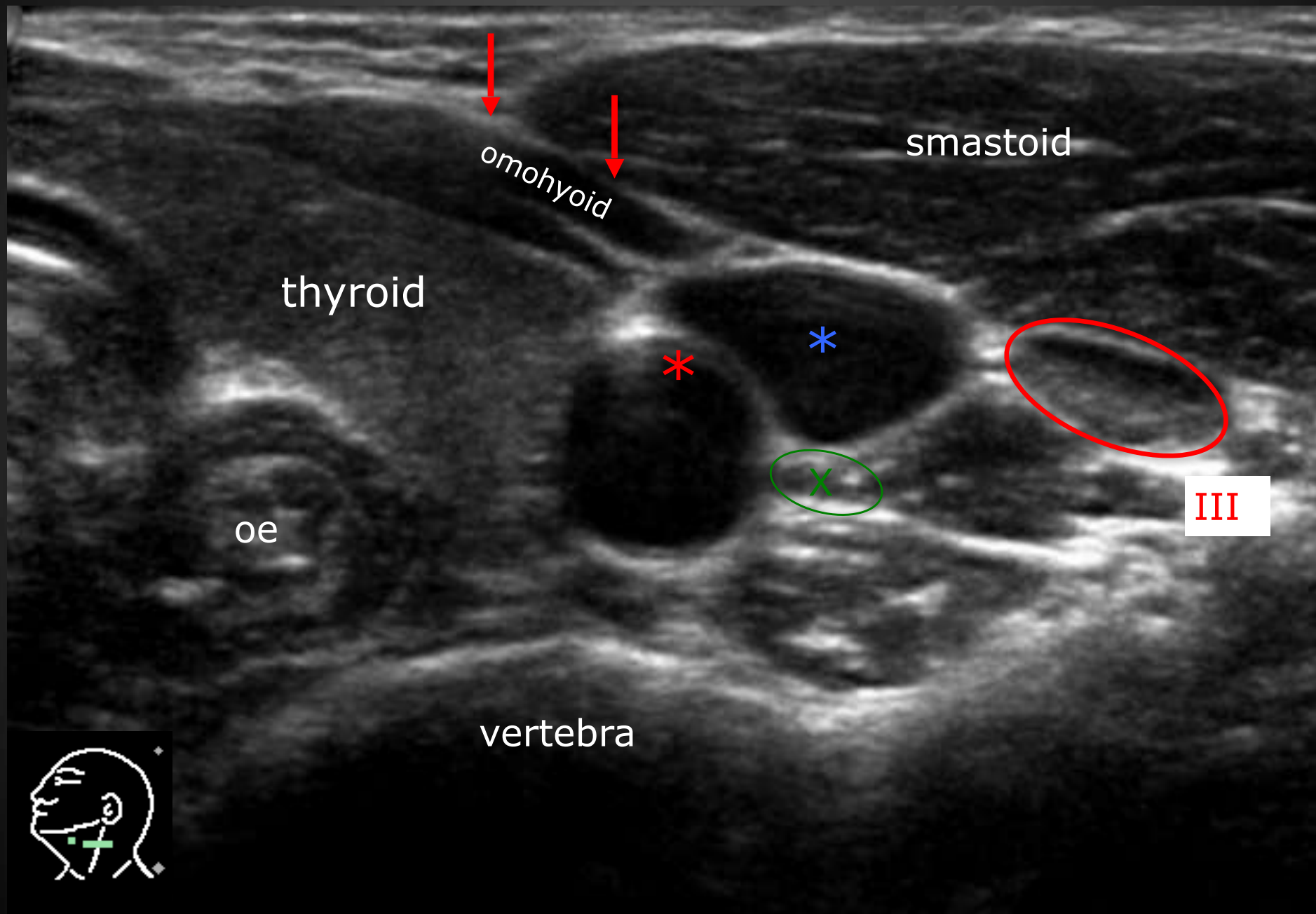
- Angle of jaw to scj
- Follow IJV

Sweep 4: deep cervical chain

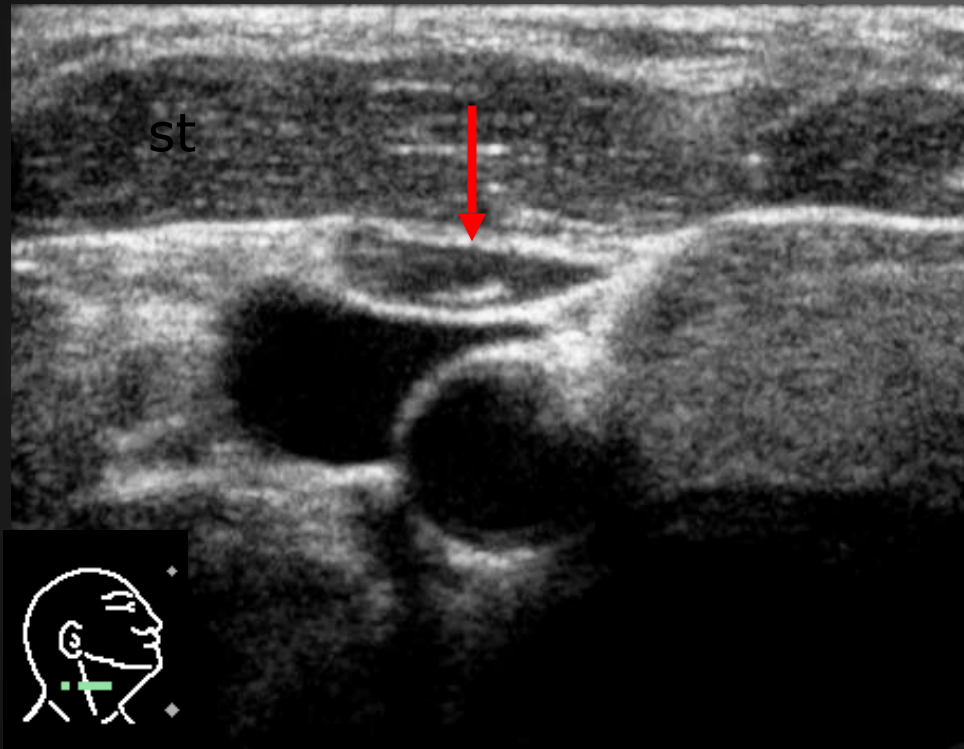


JDG node /Level II

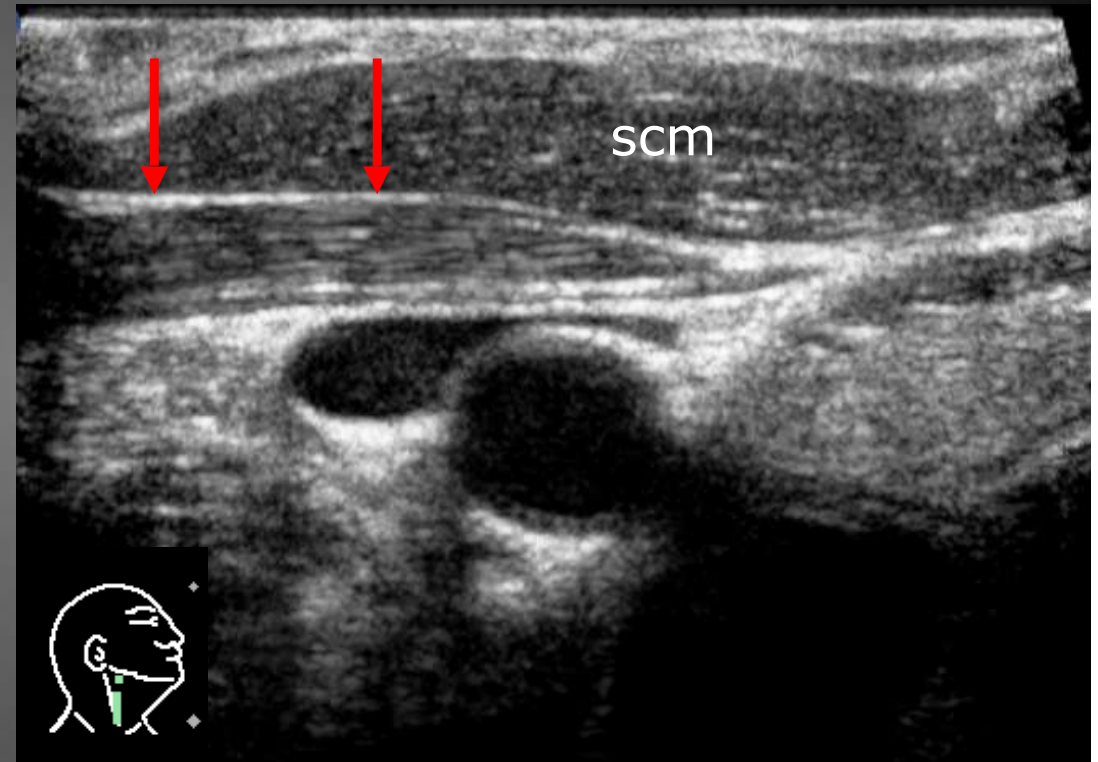
Sweep 4: deep cervical chain



Sweep 4: deep cervical chain



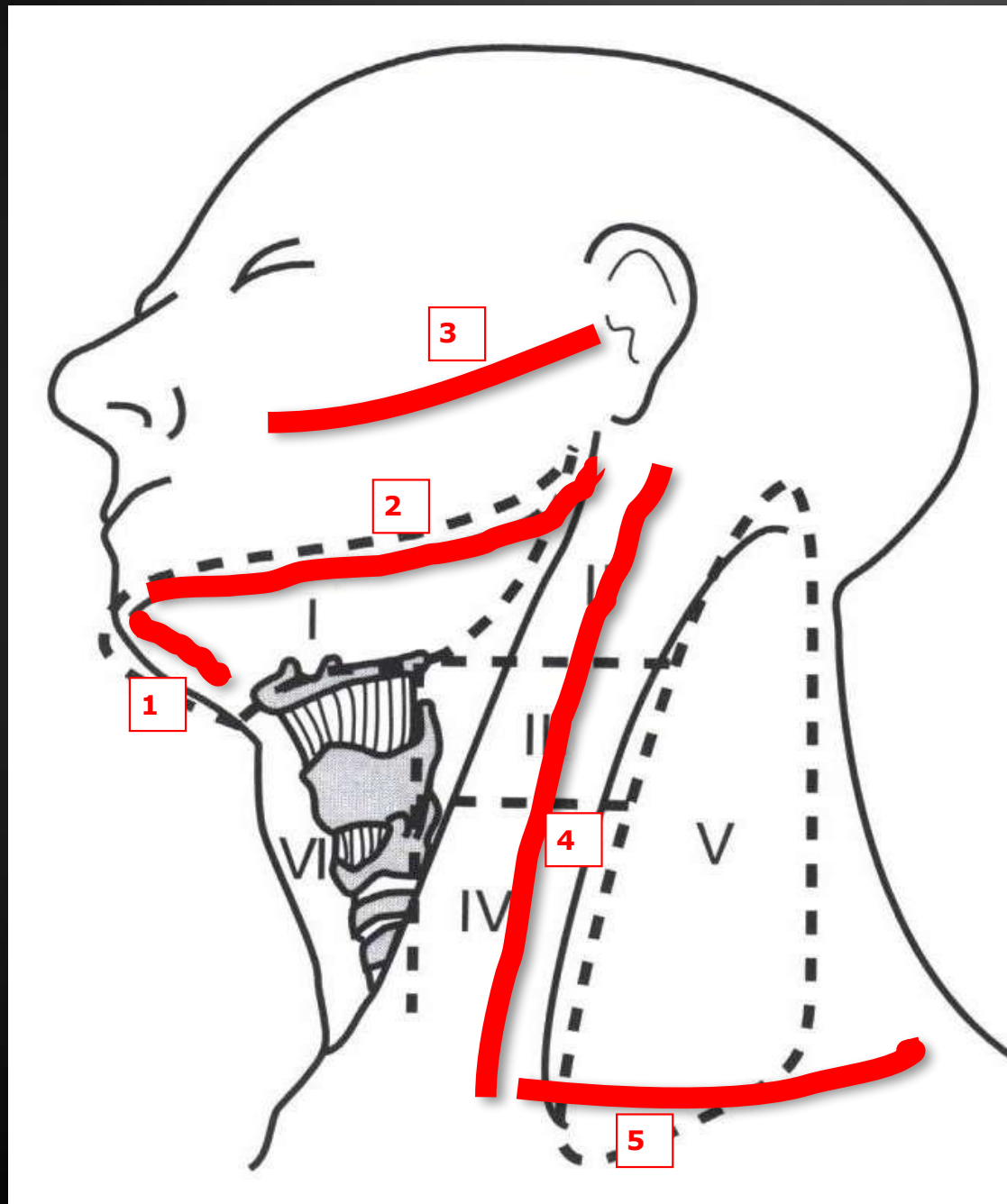
transverse



long

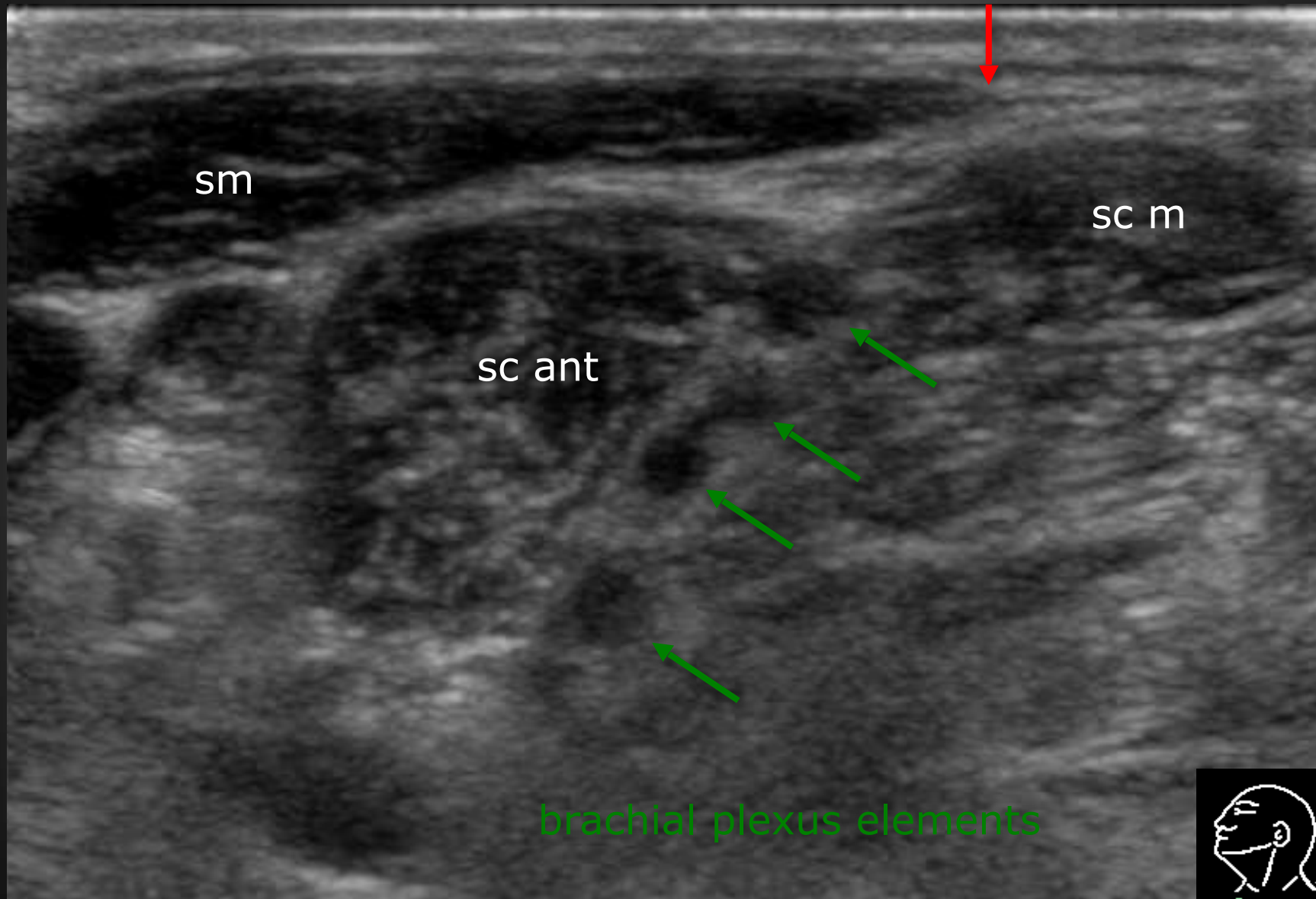
omohyoid

Sweep 5: transverse cervical

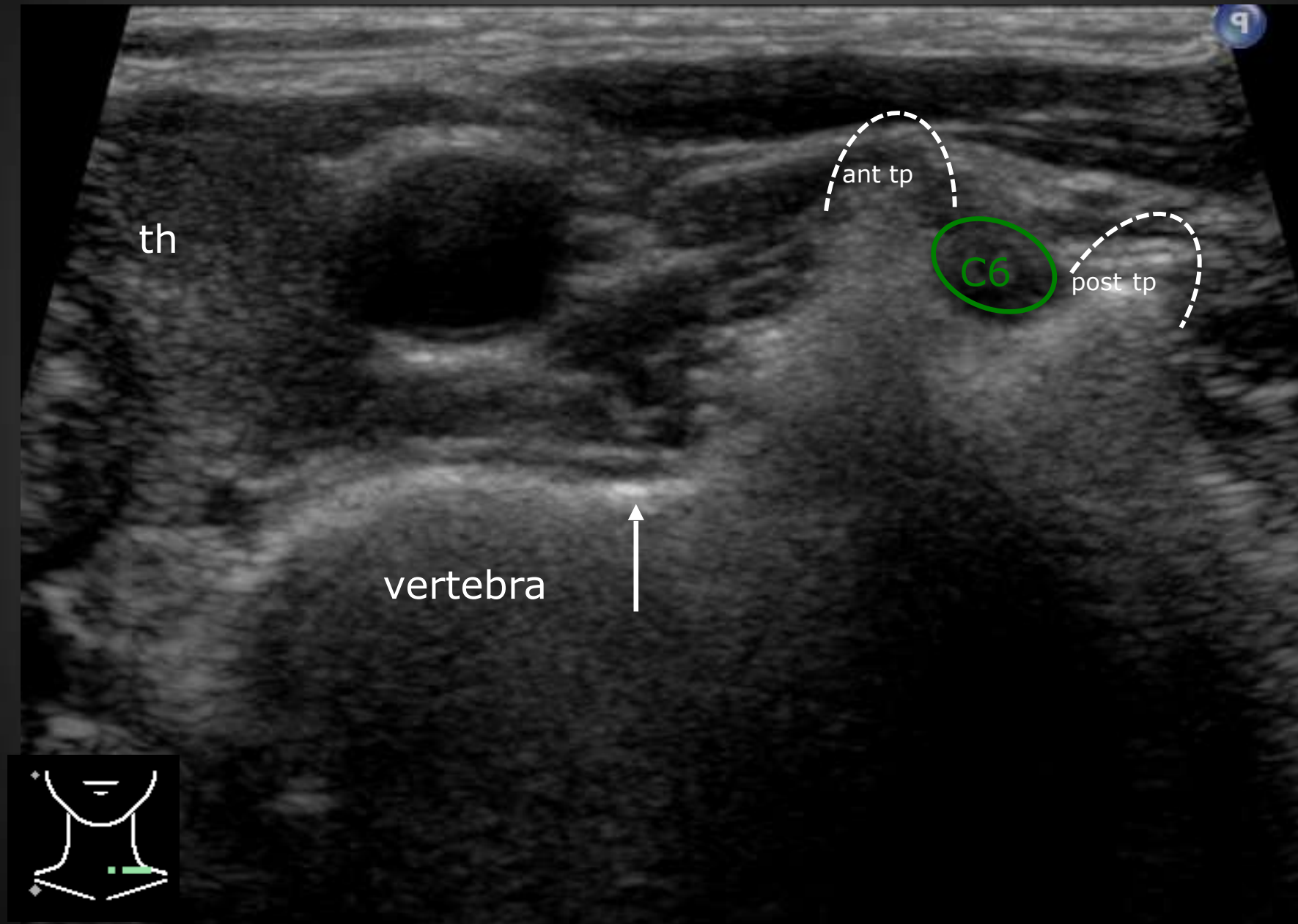


- Scj to acj
- Follow clavicle
- Sternomastoid to trapezius

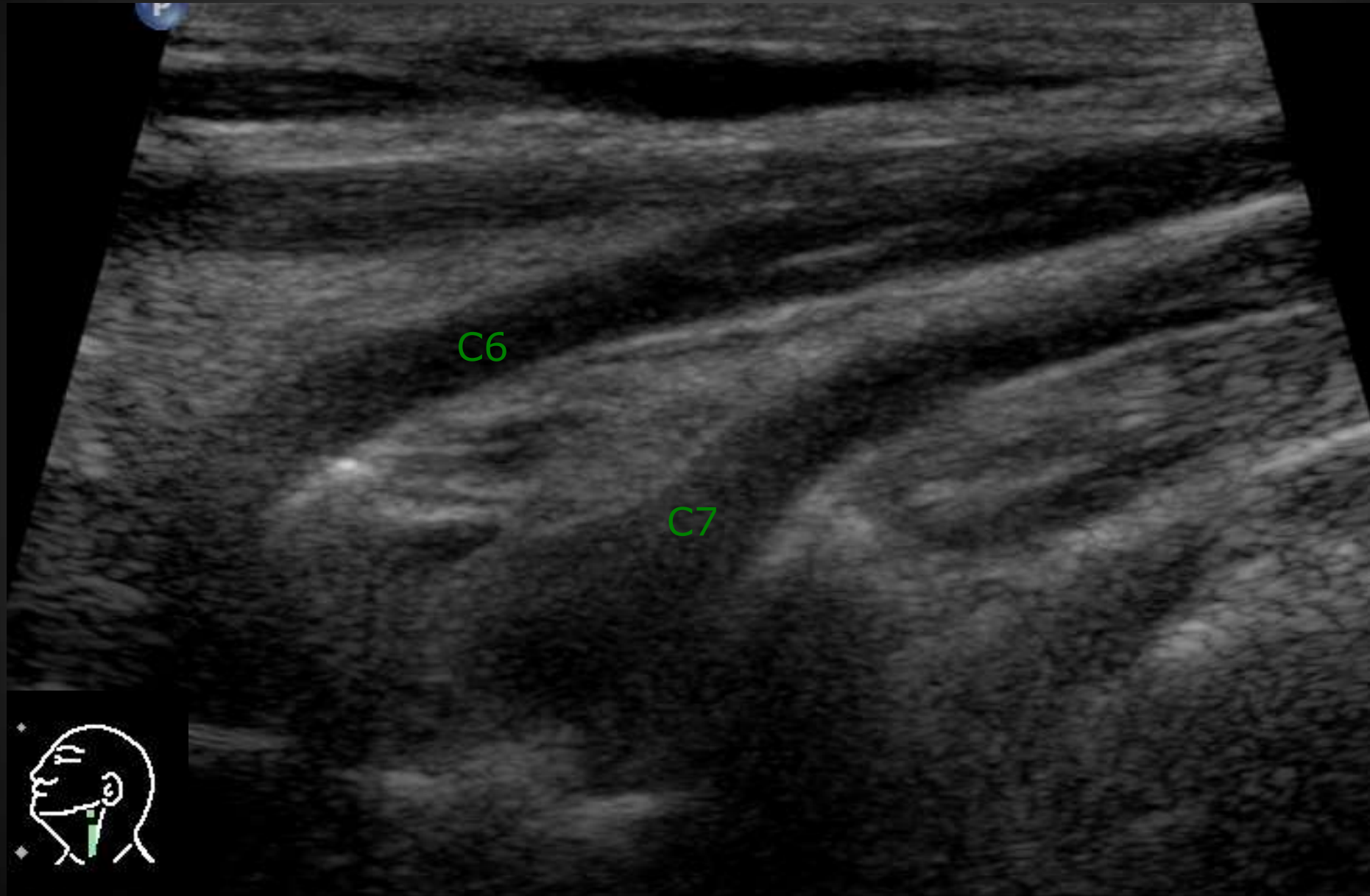
Sweep 5: transverse cervical



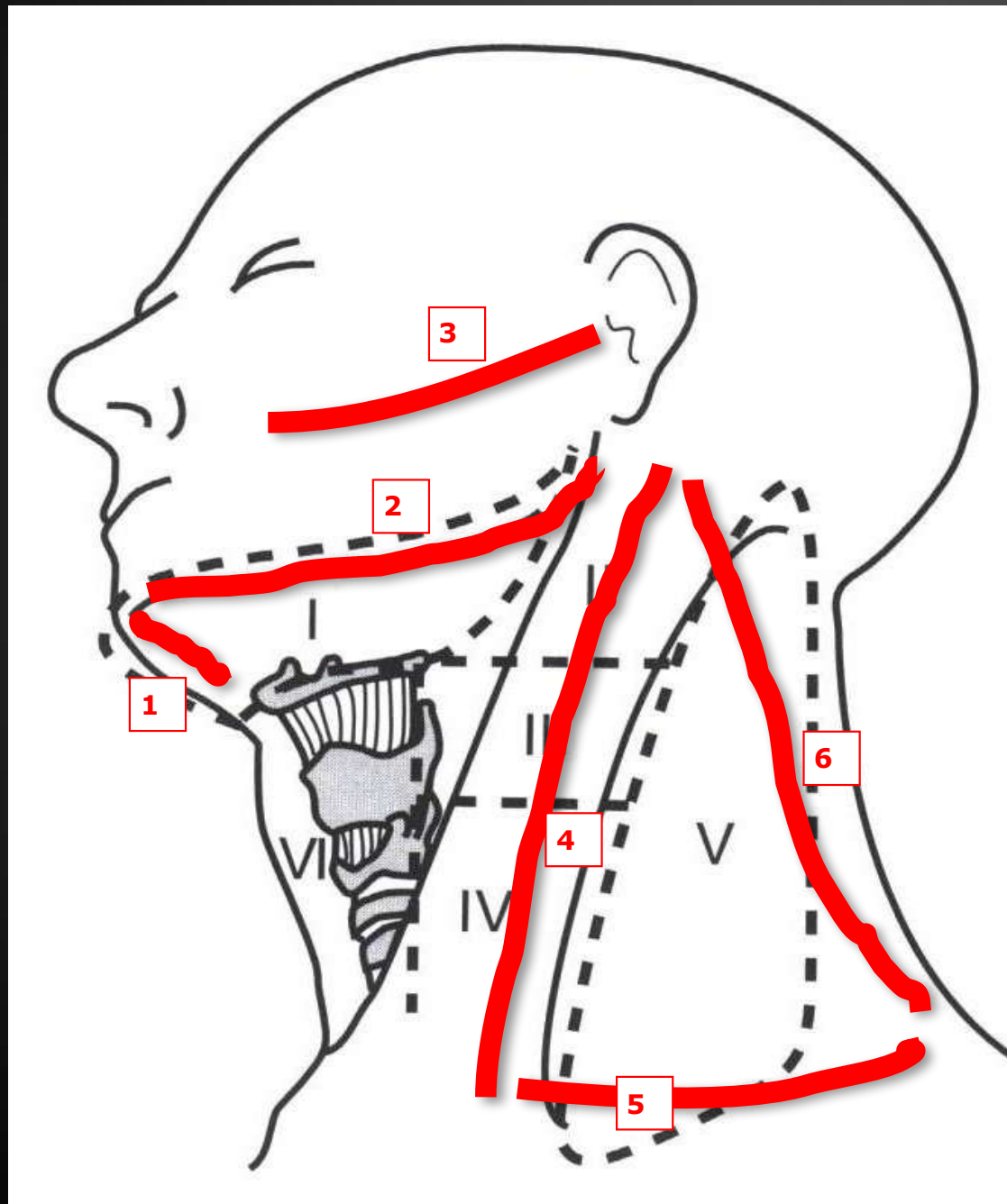
Sweep 5: transverse cervical



Sweep 5: transverse cervical

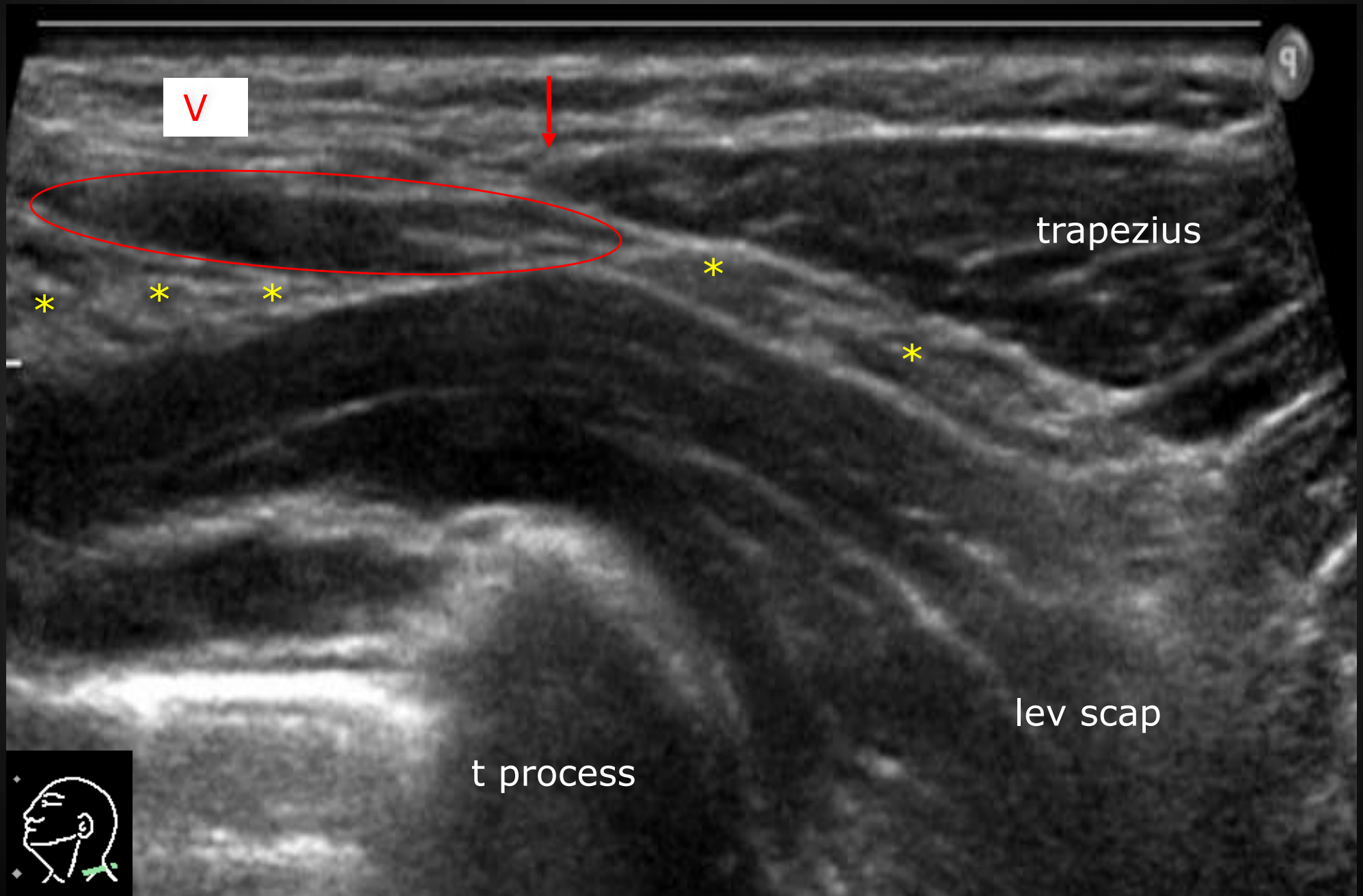


Sweep 6: posterior triangle

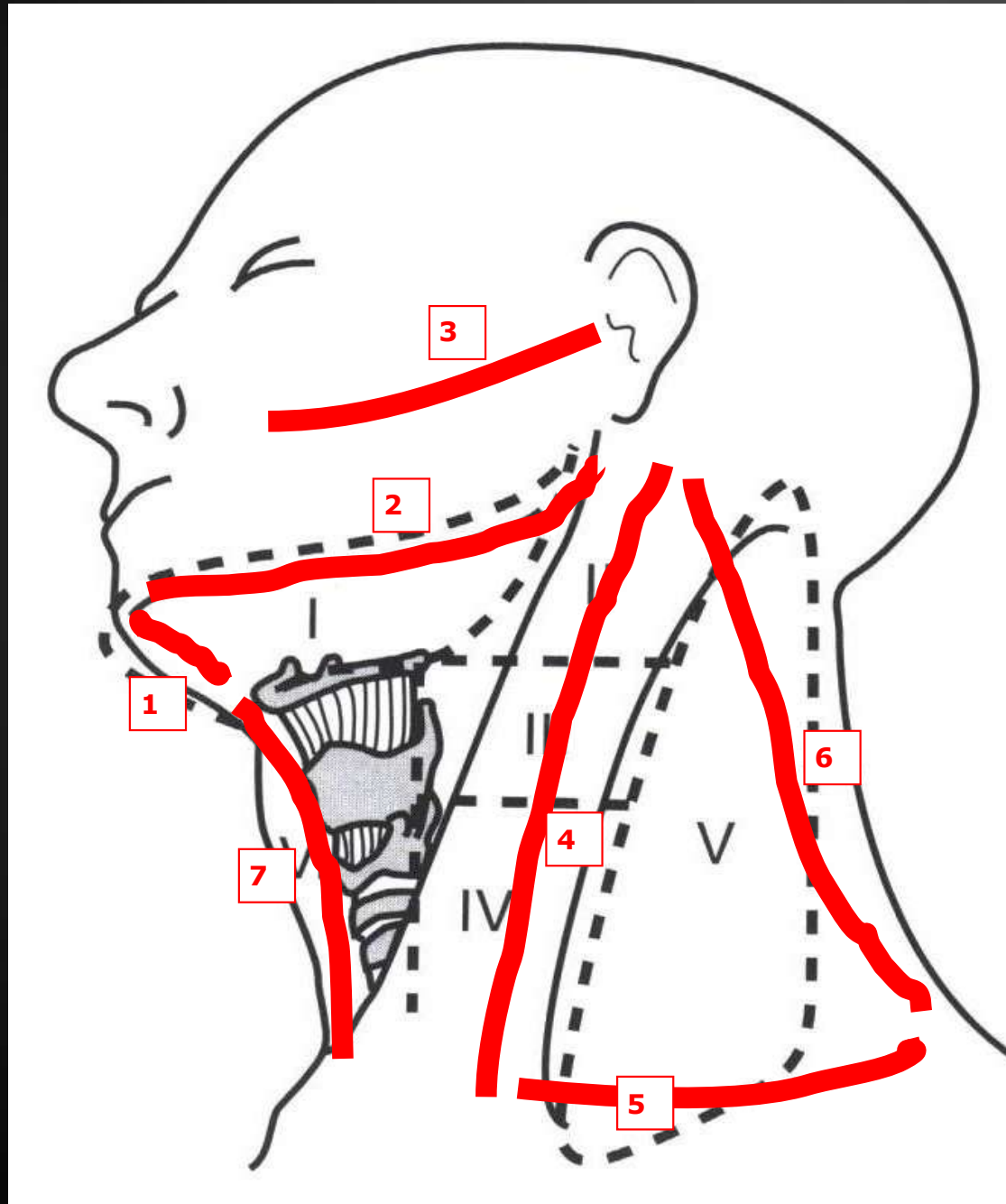


- Acj to mastoid tip
- Follow ant border trapezuis

Sweep 6: posterior triangle

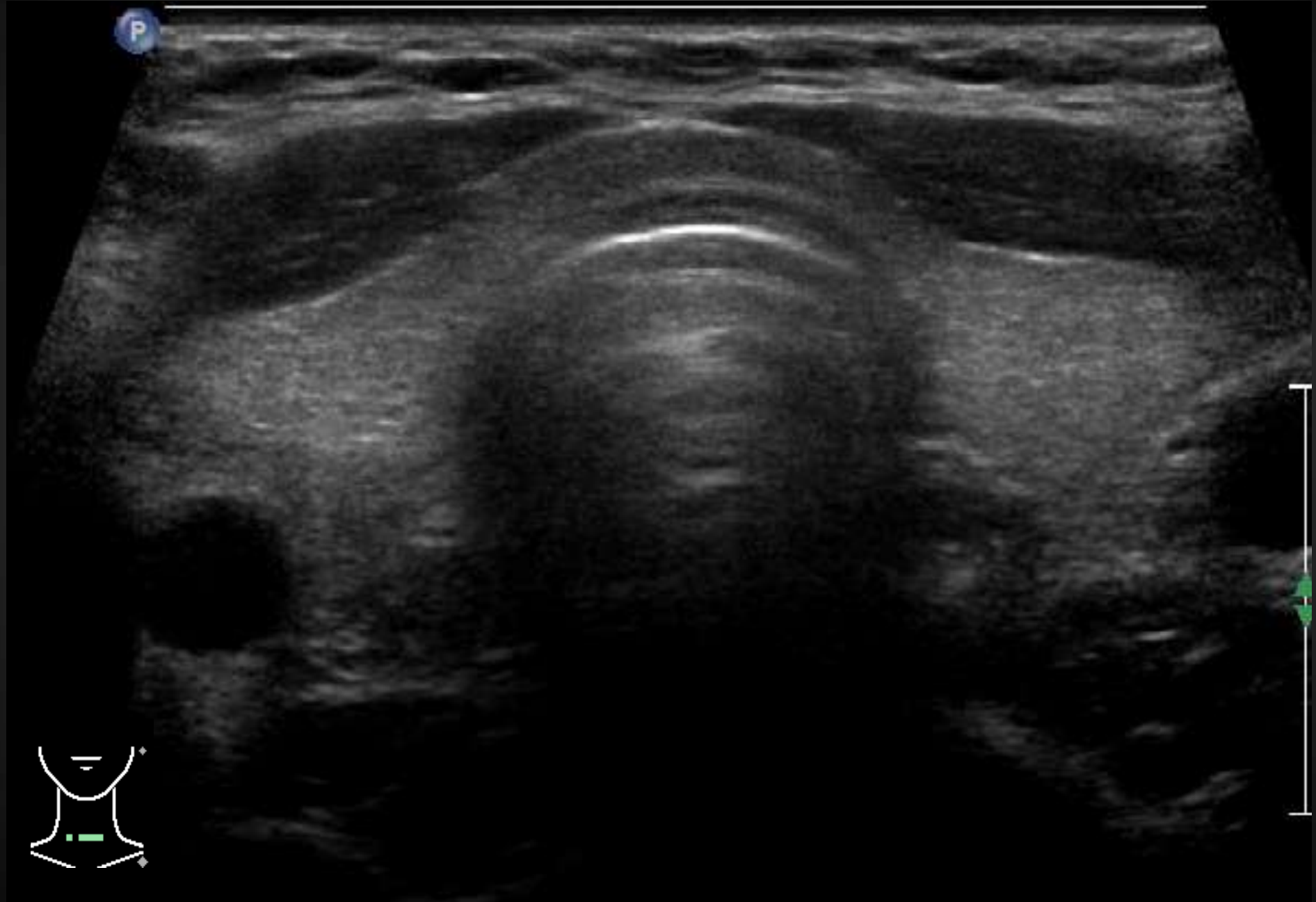


Sweep 7: anterior neck

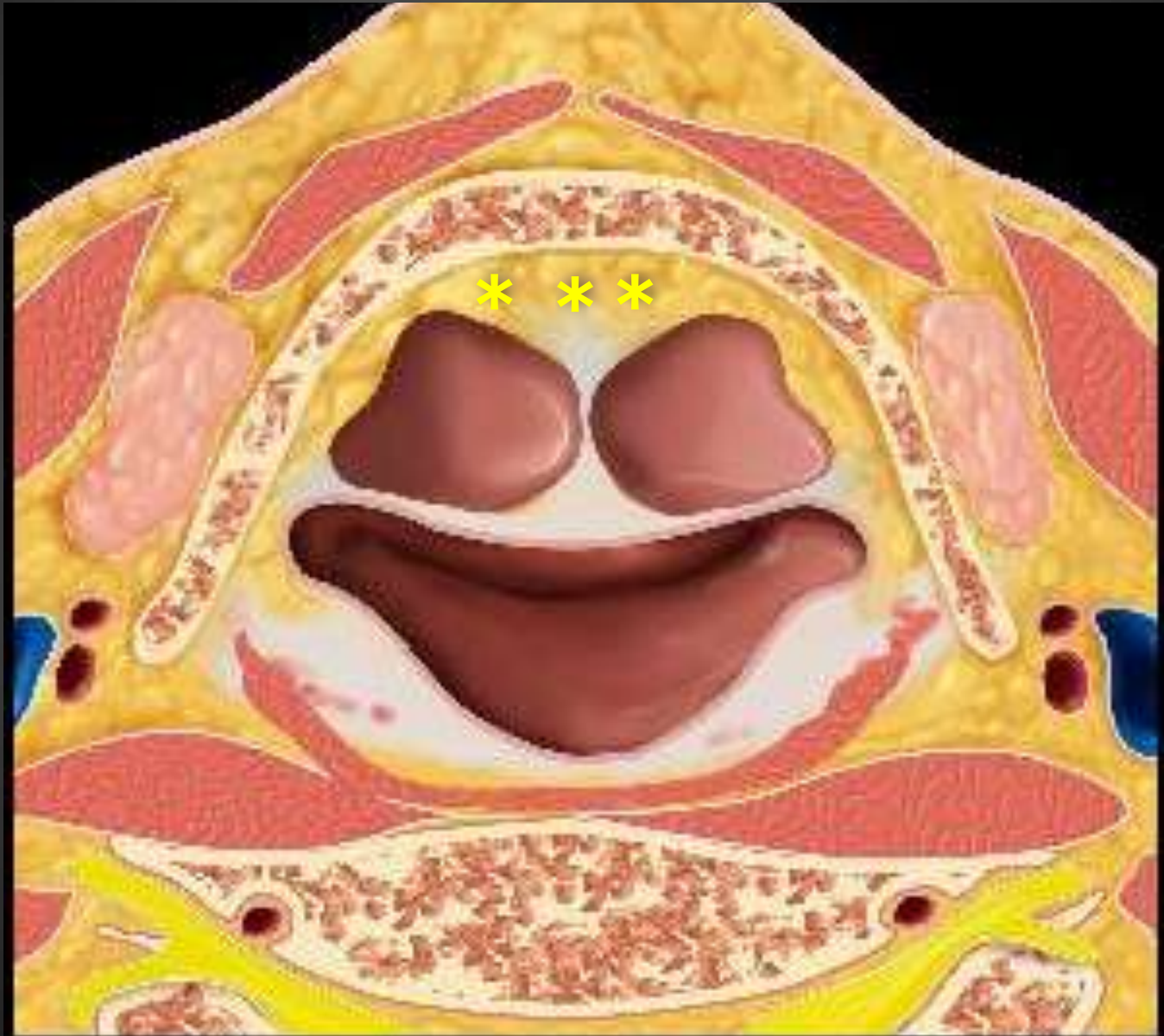


- Hyoid to sternal notch
- Thyroid and Larynx

Sweep 7: anterior neck

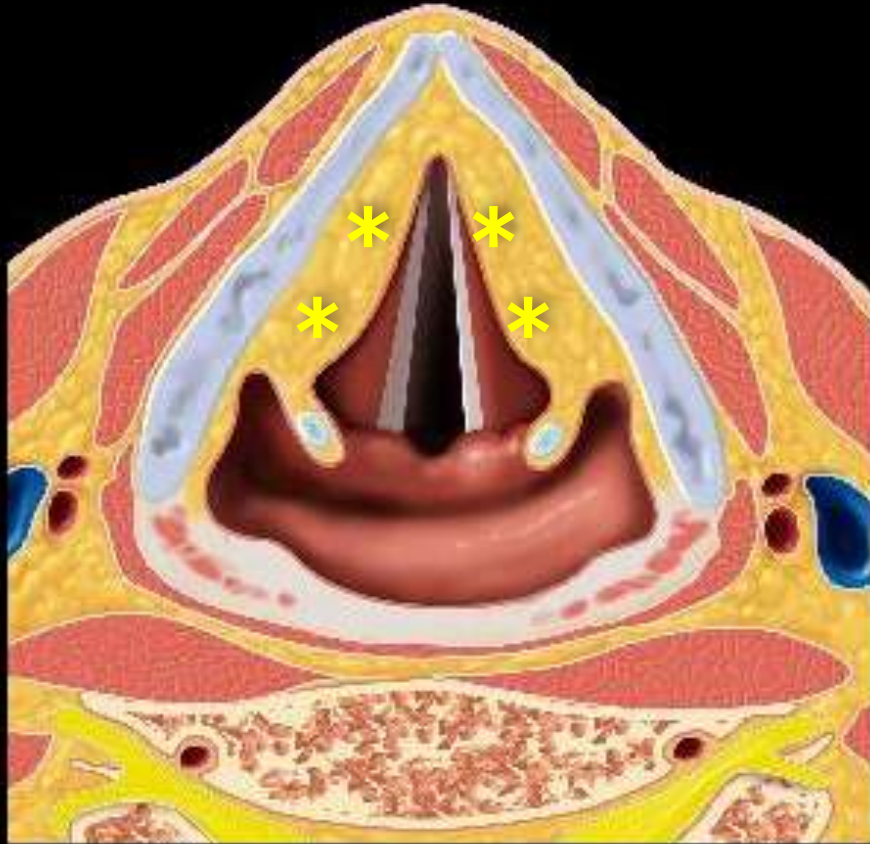


Sweep 7: anterior neck - anatomy



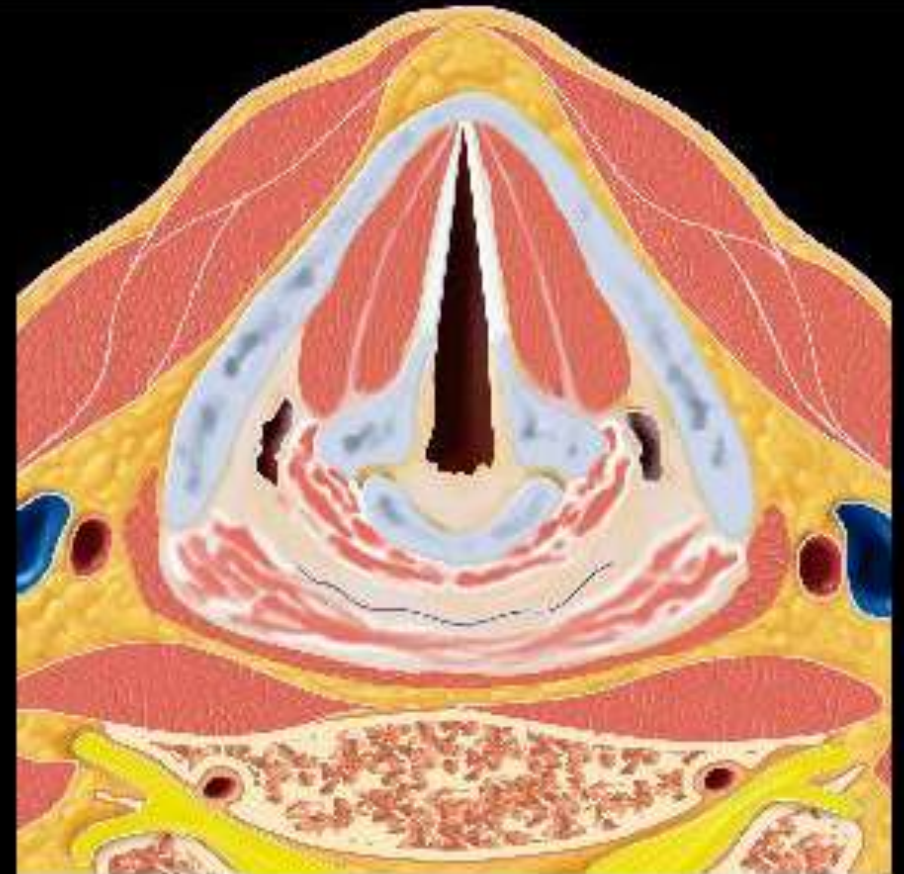
pre epiglottic fat

Sweep 7: anterior neck - anatomy



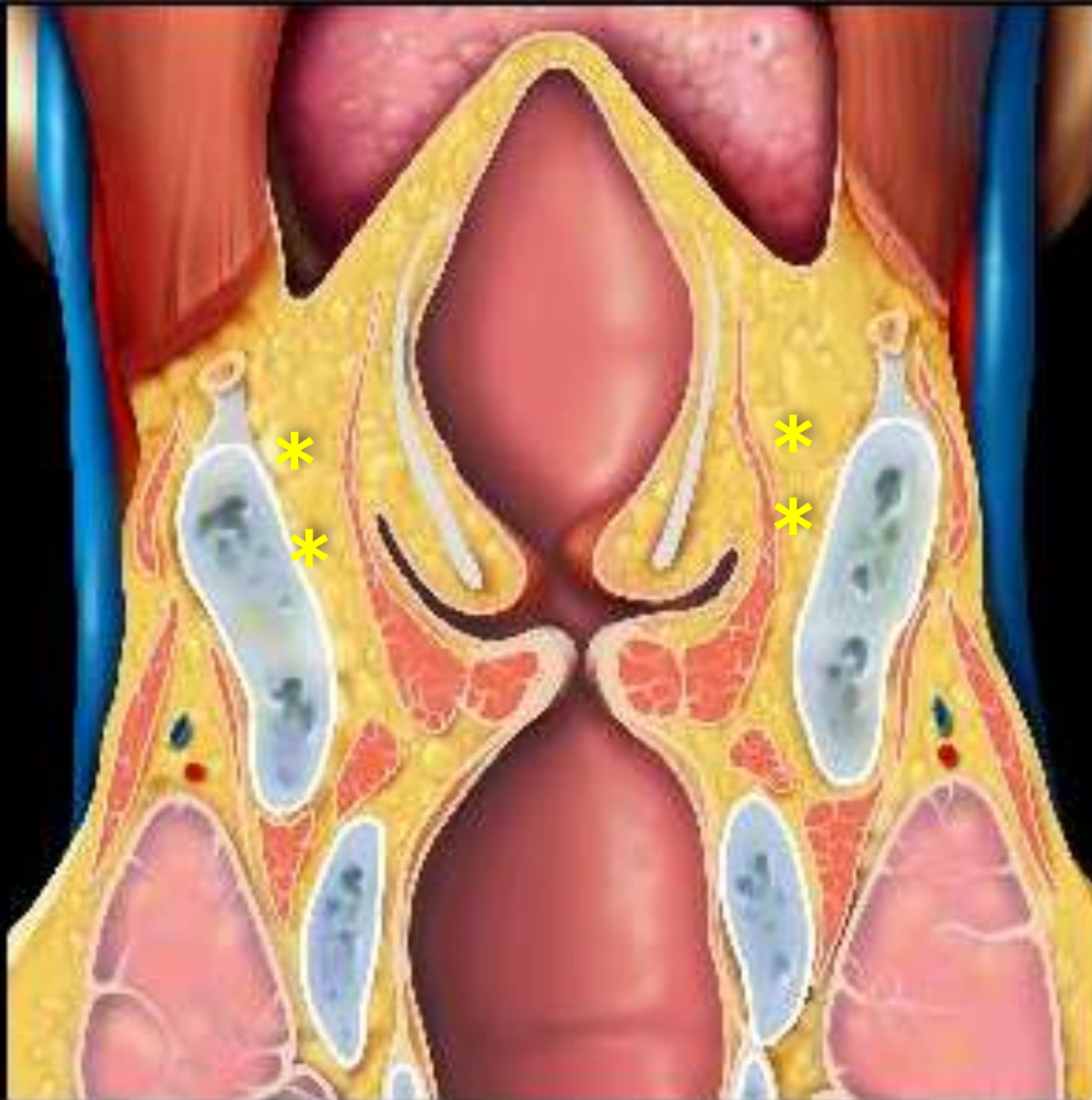
false vocal cords

paraglottic fat



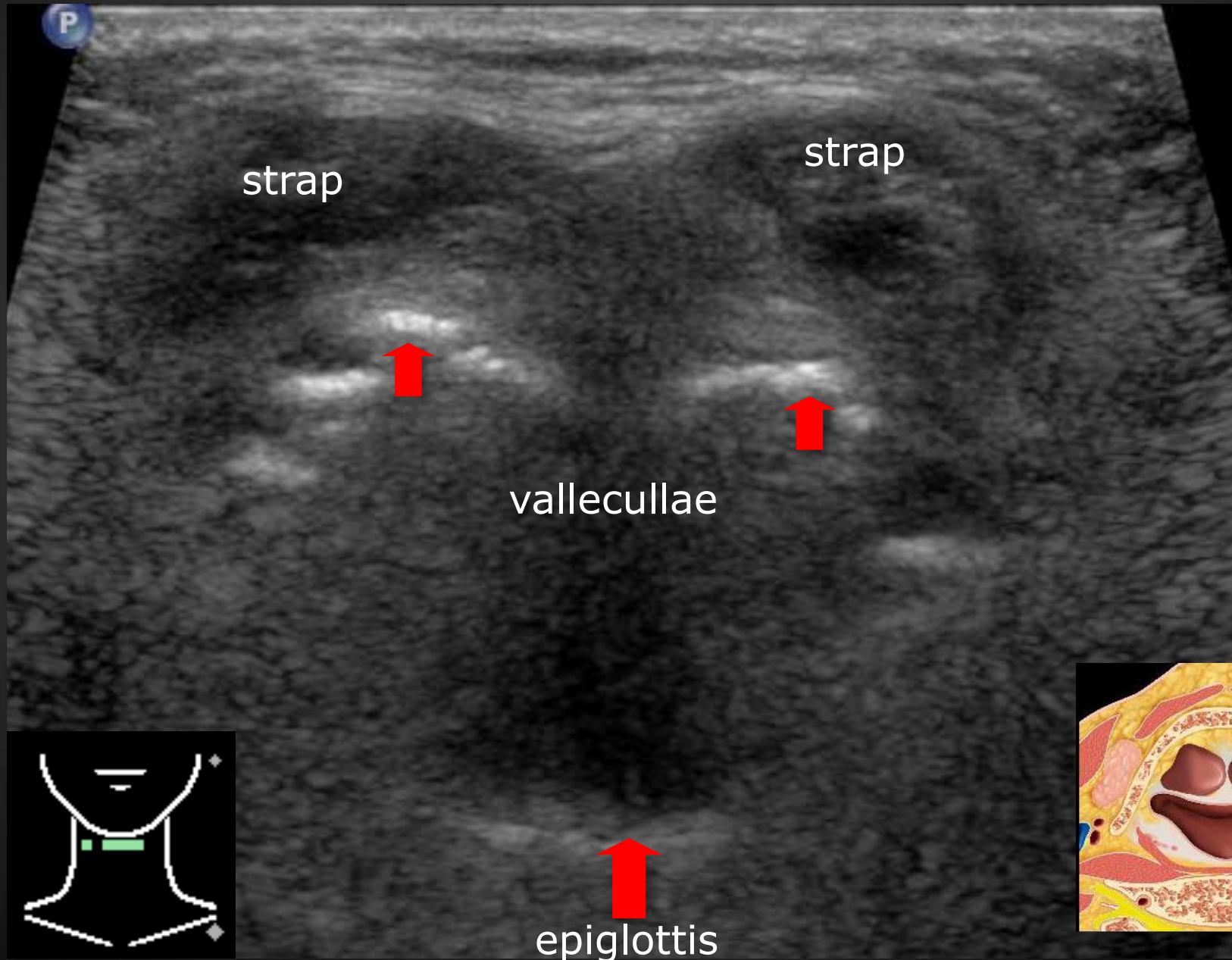
true vocal cords

Sweep 7: anterior neck - anatomy

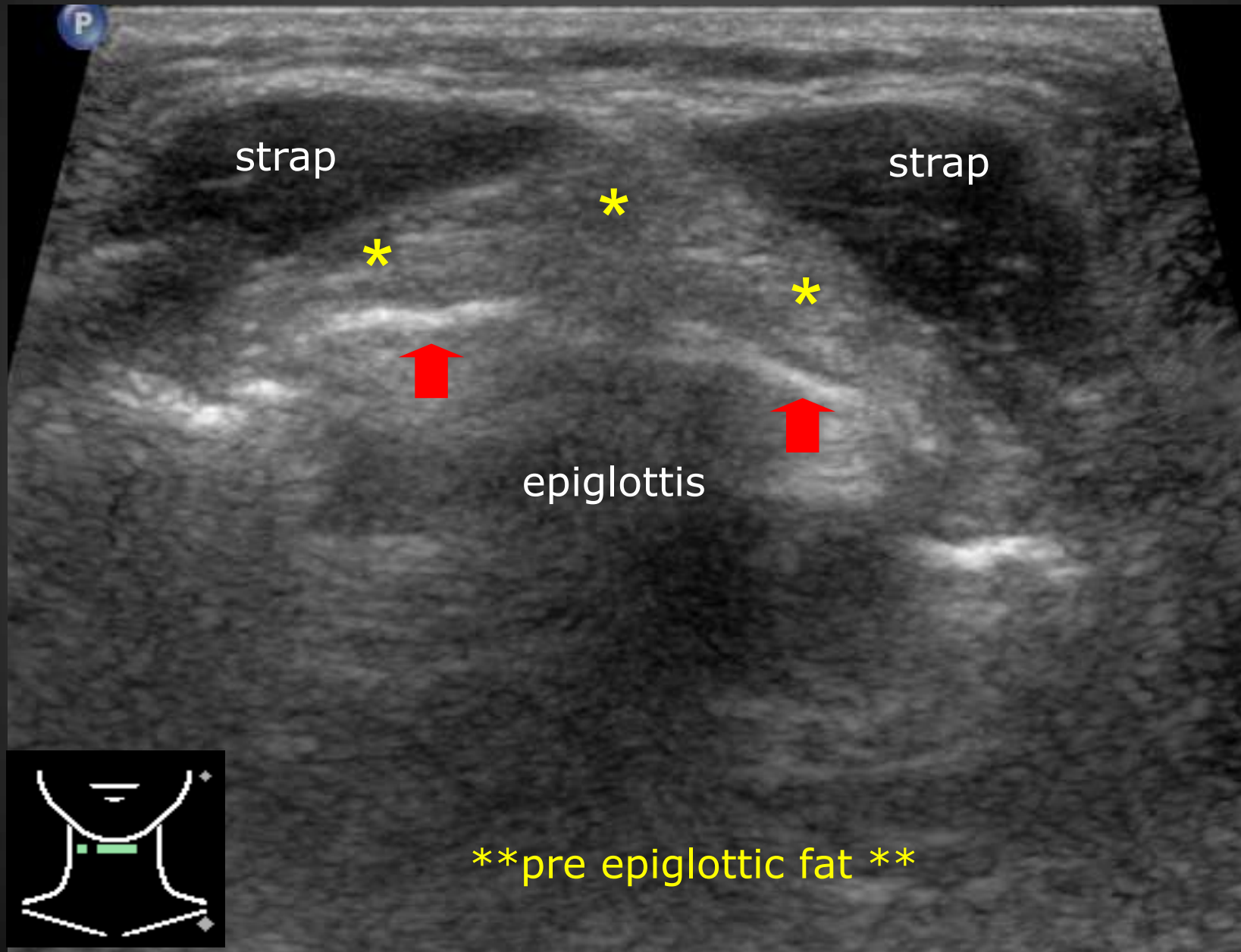


paraglottic fat

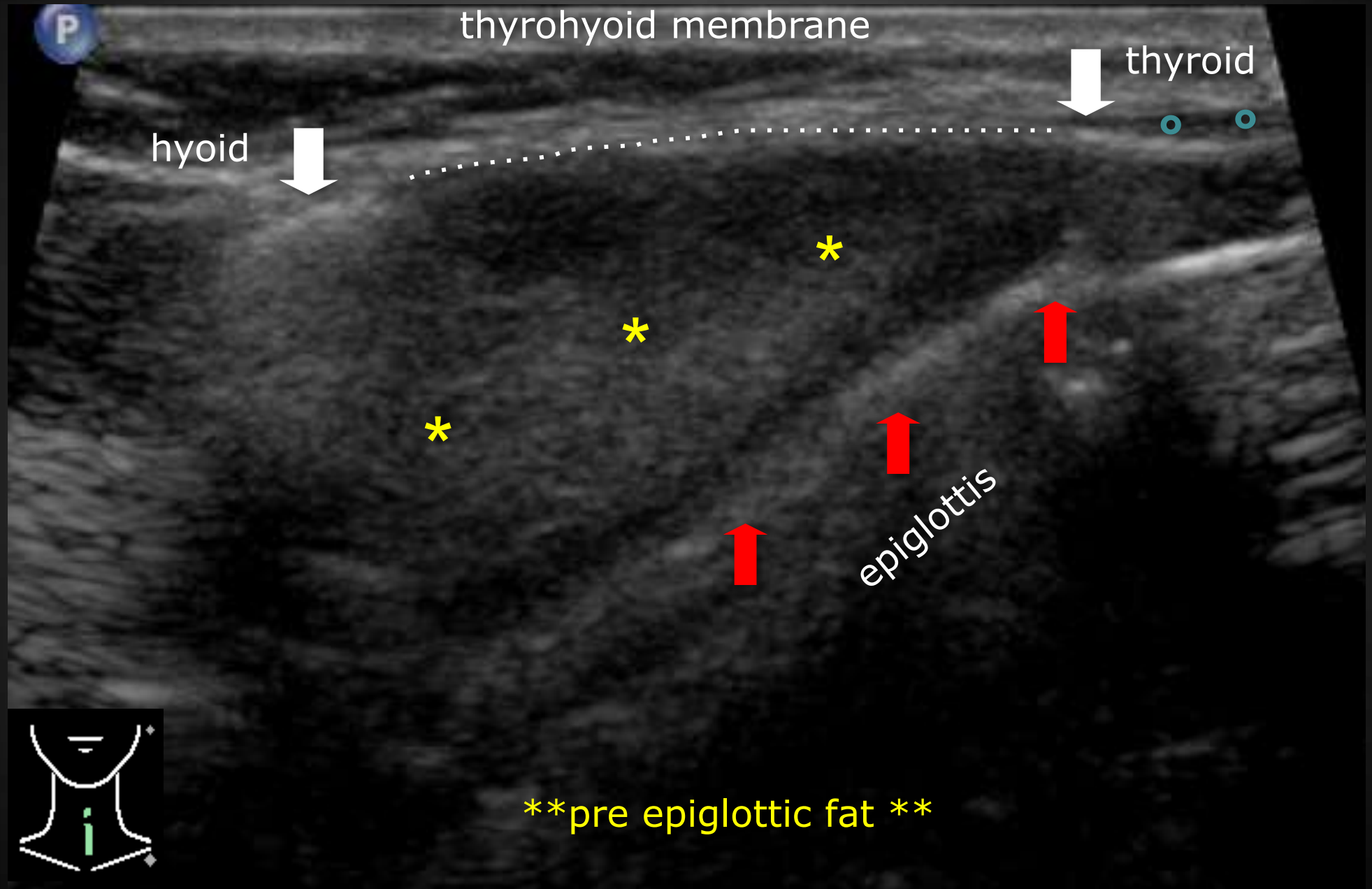
Sweep 7: anterior neck



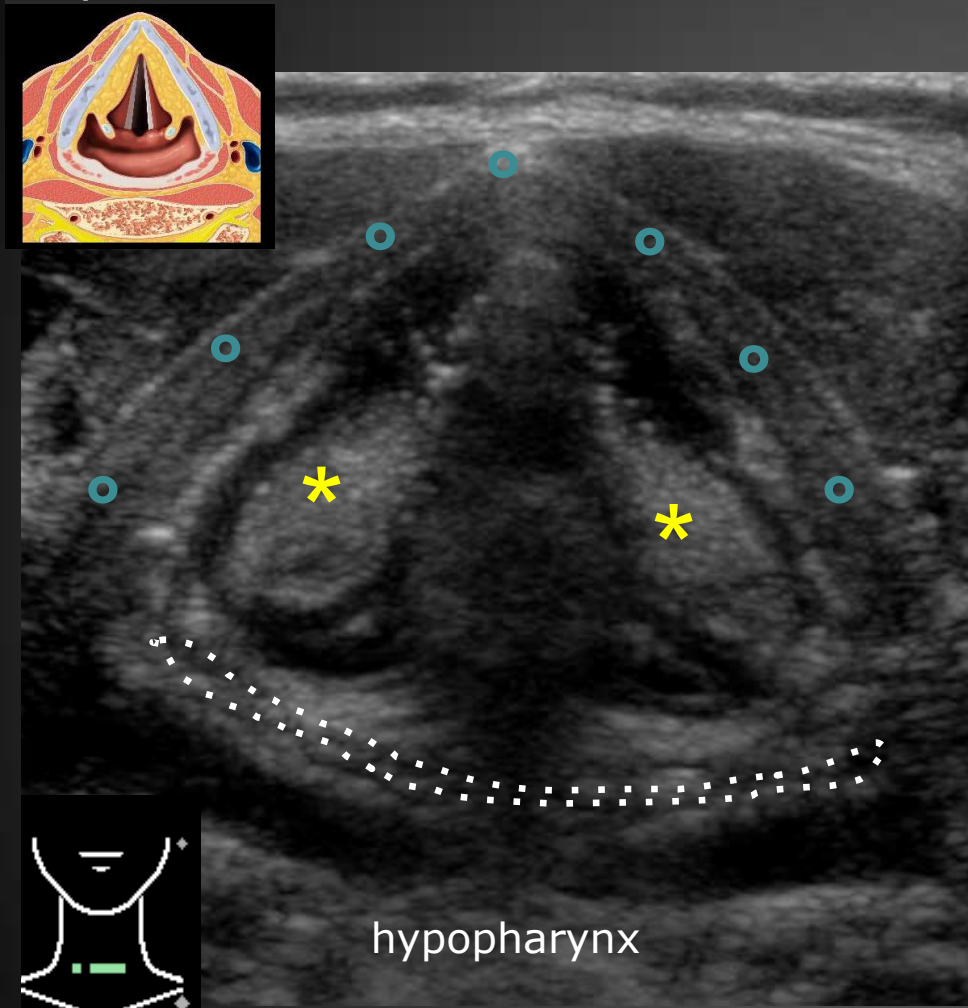
Sweep 7: anterior neck



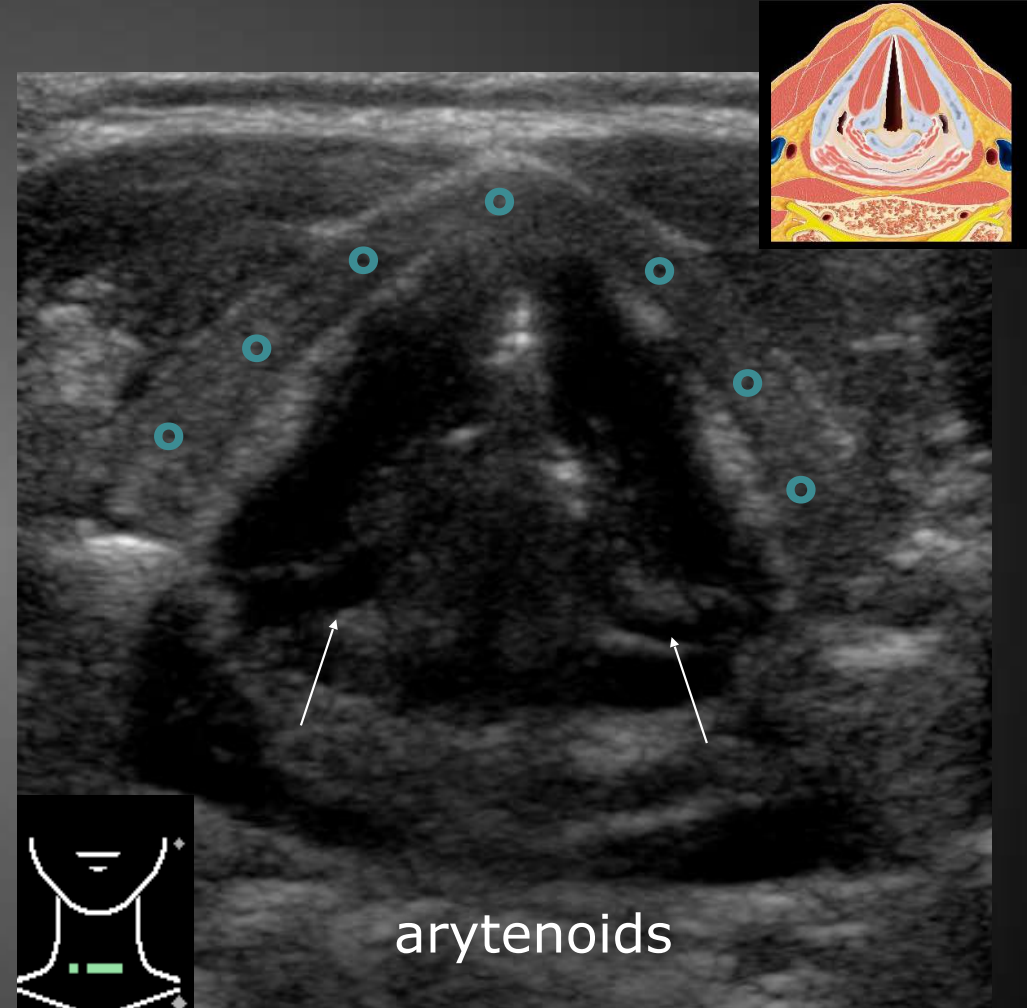
Sweep 7: anterior neck



Sweep 7: anterior neck

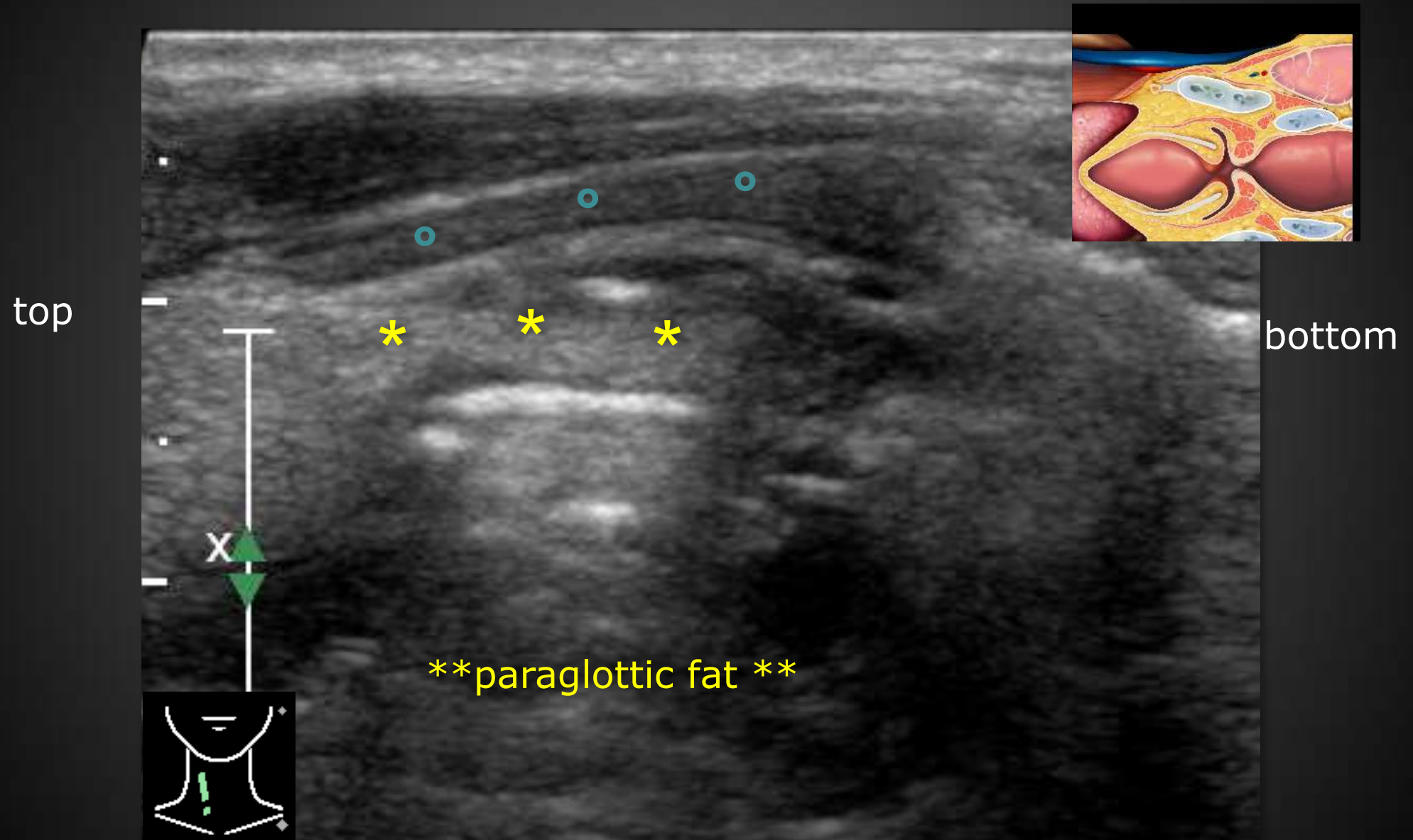


****paraglottic fat****
false vocal cords

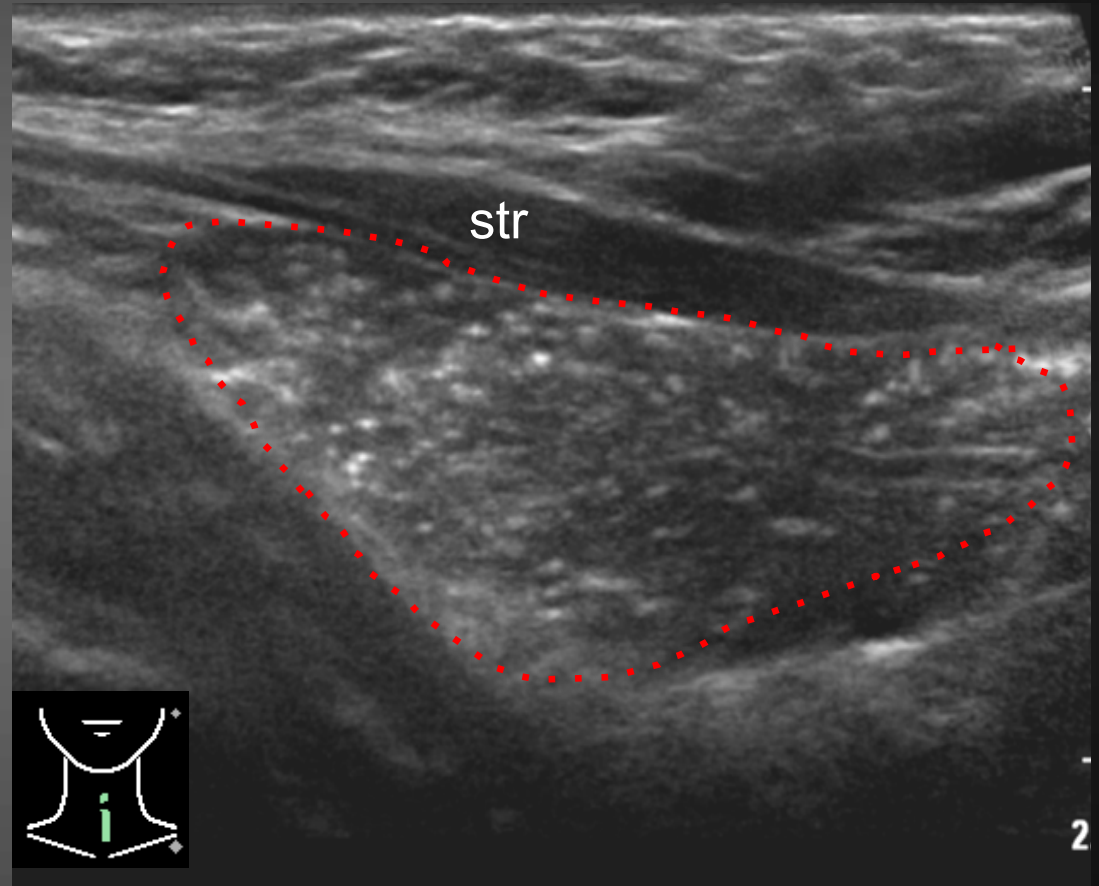
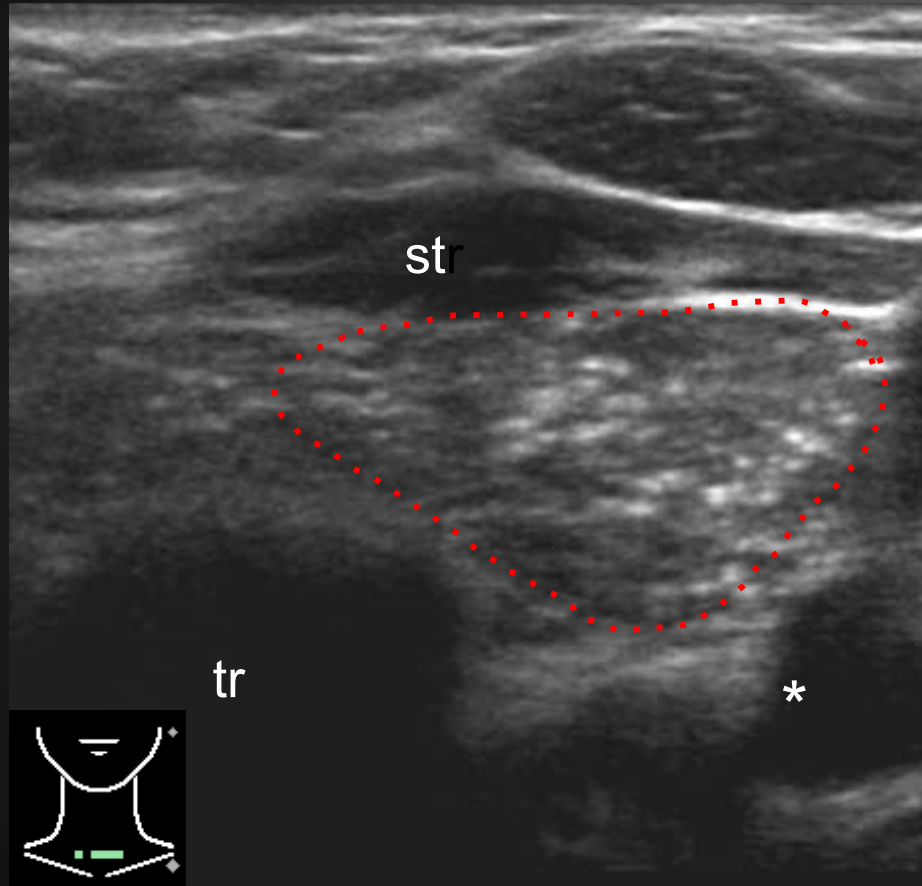


true vocal cords

Sweep 7: anterior neck



Sweep 7: anterior neck



thymus

Ultrasound of the neck in 7 sweeps

